RAPID CITY REGIONAL HOSPITAL

May 9, 2005

Coverage and Analysis Group
Centers for Medicare and Medicaid Services
7500 Security Blvd. (Mailstop C1-09-06)
Baltimore, MD 21244

Re: Formal Request for NCD Reconsideration- Tumor Antigen by ImmunoassayCA125 (40-17)

To Whom It May Concern:

I am writing to request reconsideration of the above listed NCD. Specifically, I am requesting that ICD-9 codes 158.8, 158.9, and 159.8 for primary peritoneal adenocarcinoma be added to the policy for coverage. Such additions will allow for greater coverage of diagnostic and staging methodologies for female Medicare beneficiaries diagnosed with primary peritoneal cancer.

Attached you will find substantial medical literature supporting the effectiveness of utilizing the CA125 in the diagnosing and staging of these types of cancers. As the medical literature states, primary peritoneal cancer mimics ovarian cancer. Thus, the CA125 tumor maker can playa vital, cost effective role in early detection, staging, and monitoring of treatment for patients living with primary peritoneal cancer. Additionally, the treating oncologists have provided a summary of this information and support the addition of the above listed codes.

Thank you for your time and review of this request. Should you have any questions, please contact me at (605) 719-5687.

Sincerely,

Carly Elliott, RN, BSN, CPC
Medical Compliance Auditor

JOHN T. VUCUREVICH
REGIONAL
CANCER CARE INSTITUTE
353 Fairmont Boulevard Rapid City, SD 57701 (605) 719-2300 FAX (605) 719-2310

April 14, 2005

Attention:
Cahaba Medical Director

To Whom It May Concern:

We are writing to request reconsideration of coverage of Carboplatin and Taxol, as well as CA-125 monitoring in patients with primary peritoneal adenocarcinoma. Please find attached studies and literature supporting the use of these drugs as a first line treatment for primary peritoneal adenocarcinoma. Also attached is literature supporting the use of CA-125 testing as a tool in the monitoring of the progression of this disease. Based on the literature attached, as well as what would be our standard of care, we feel very strongly that this regimen is appropriate in the treatment of primary peritoneal adenocarcinoma.

As referenced in the Compendia Based Drug Bulletin, Association of Community Cancer Centers, Vol. 13, No.4, November 2004, Carboplatin is indicated in the treatment ofboth ovarian and peritoneal cancer. This indication is also recognized by the United States Pharmacopeial Convention, Inc., as referenced in the aforementioned ACCC Compendia. Primary peritoneal and primary ovarian serous carcinoma has virtually indistinguishable morphology, and studies clearly show that platinum-paclitaxel chemotherapy regimens have efficacy in the initial management ofprimary peritoneal carcinoma. Carboplatin or cisplatin in conjunction with paclitaxel is currently recognized as first-line chemotherapy.

Studies have also shown rising CA-125 levels exhibit similar patterns in peritoneal serous papillary carcinomas as in ovarian cancer prior to clinical detection. The biological behavior as well as the histopathological features of primary serous peritoneal carcinoma are identical to those of ovarian papillary serous carcinoma. CA-125 is vital in monitoring response to therapy in both disease states. They are, in essence, the same disease.

We formally request a reconsideration of your coverage guidelines in relation to use of Carboplatin and Taxol in the treatment of peritoneal serous papillary carcinoma. We also request reconsideration of utilization of CA-125 for accurate diagnosis and treatment planning. Your reconsideration in this matter is greatly appreciated. Literature supporting these requests is attached for your review.

Sincerely,

Richard Tenglin, MD
Medical Oncologist/Hematologist

Mark Schroeder, MD
Medical Oncologist/Hematologist

David Bartsch, MD
Medical Oncologist/Hematologist

Larry Ebbert, MD
Medical Oncologist/Hematologist

JOHN T. VUCUREVICH
REGIONAL
CANCER CARE INSTITUTE
353 Fairmont Boulevard Rapid City, SD 57701 (605) 719-2300 FAX (605) 719-2310

April 14, 2004

Addendum:

Use of Paclitaxel is referenced in the Compendia Based Drug Bulletin, Association of Community Cancer Centers, Vol. 13, No.4, November 2004 as indicated for use in the treatment of peritoneal and ovarian cancer.

Compendia-Based
DRUG BULLETIN
Vol. 13, No. 4 November 2004
Association of Community Cancer Centers

President's Message

New Proposals From CMS

On November 1, 2004, the Centers for Medicare & Medicaid Services (CMS) announced that $300 million is earmarked for a quality of care one-year demonstration project beginning in January 2005. The funding will pay physicians who furnish chemotherapy in the office an additional $130 per patient encounter. To qualify for the extra payment in the Medicare demonstration project, a practicing practitioner will need to assess and document the severity of a patient's status with respect to nausea and/or vomiting, pain, and fatigue. Physicians will be required to use 12 new G-codes established for this purpose in order to document the specified services related to these three factors at the start of each chemotherapy session. This payment- increase is above any increase in the new and revised drug administration codes that CMS plans to implement in 2005.

According to CMS, the demonstration is intended to measure and improve the quality of care provided to Medicare patients.

CMS also announced plans to pay for four colon cancer drugs, including oxaliplatin (Eloxatin), irinotecan (Camptosar), bevacizumab (Avastin), and cetuximab (Erbitux) when those therapies are used in any of nine clinical trials that will test their effectiveness against other cancers. This means that Medicare will pay for these treatments for uses not listed as "indicated" on the drug label or in one of the major drug compendia specified in the Medicare statute. The trials are sponsored in part by the National Cancer Institute (NCI).

CMS has also proposed to expand coverage for positron emission tomography (PET) scans for cervical cancer, as well as the expansion of PET scans for the diagnosis and staging of a broad range of additional types of cancer when certain requirements are met.
ACCC looks forward to additional details on these proposals and to working with CMS on the process.

CMS's announcement preceded the release of the final Physician Fee Schedule rule, which at press time had not been released. The Physician Fee Schedule regulation will provide details on the drug administration reimbursement adjustments and include average sales price (ASP) data. These ASP data will be based on second Quarter 2004 drug sales, which will be incorporated into CMS's updated estimate of the impact of Medicare payment changes on community cancer care.

The Association of Community Cancer Centers' *Compendia-Based Drug Bulletin* is published in February, May, August, and November as a service to ACCC members and other cancer care providers. If you have queries regarding the *Bulletin*, contact Donald Jewler, Publications Director, ACCC, 11600 Nebel St., Suite 201, Rockville, MD 20852, 301/984-9496. Copyright ©2004 by the Association of Community Cancer Centers. USP DI® is a copyrighted publication of Micromedex, Inc., a subsidiary of Thomson Publishing Corp. All Rights Reserved. USP DI® is a registered trademark of the United States Pharmacopeia used under license by Micromedex, Inc., a subsidiary of Thomson Publishing Corp. Permission granted. *AHFS Drug Information* is a copyrighted publication of the American Society of Health System Pharmacists, Inc. Permission granted. Local Medicare policy supersedes any coding provided in this publication. Always check your local Medicare updates as they may include indications not listed in the compendia.

Generic Drug Index – ANTINEOPLASTICS AND THEIR ADJUNCTS

AGENT	Indication(s)	ICD-9 Code(s)
Abarelix (Plenaxis) C9216 10 mg	Prostate	185._
Alemtuzumab (Carnpath) J9010 10 mg	Chronic Lymphocytic Leukemia	204.1_
Alitretinoin (Panretin)	Kaposi's Sarcoma (topical)	176._
Altretamine (Hexa1en)	Lung[1] (small cell)	162._
Altretamine (Hexa1en)	Ovary [1]	183.0
Amifostine (Ethyol) J0207 500 mg	Bone marrow toxicity, cisplatin-and cyclophosphantide-induced (prophylaxis), advanced solid tumors	(140.0 to 203.8, 283.__ to 285.9, 995.2, V58.1, E933.1°)
Amifostine (Ethyol) J0207 500 mg	Bone marrow toxicity, cisplacin-induced (prophylaxis), head and neck carcinoma	(140.0_ to 149.0-,160._ to 161.-, 195.0,9952, V58.1, E933.1°)
Amifostine (Ethyol) J0207 500 mg	Bone marrow toxicity, cyclophosphamide-induced (prophylaxis), malignant lymphoma	(200._ to 202.-, 283.__ to 285.9, 995.2, V58.1, E933.1°)
Amifostine (Ethyol) J0207 500 mg	Bone marrow toxicity, carboplatin-induced (prophylaxis), non-small cell lung cancer	(162.0 to 162.9,283.__ to 258.9, 995.2, V58.1, E933.1°)
Amifostine (Ethyol) J0207 500 mg	Bone marrow toxicity, carboplatin-induced (prophylaxis) plus radiation therapy, head and neck carcinoma	(140._ to 149.-, 160._ to 161.-, 195.0,995.2, V58.0, V58.l)
Amifostine (Ethyol) J0207 500 mg	Myelodysplastic Syndromes[1] ***	238.7
Amifostine (Ethyol) J0207 500 mg	Nephrotoxicity, cisplatin-induced (prophylaxis),	(162.2 to 162.9, 183.-> 198.6, 172._, 583.9,995.2,

	advanced ovarian carcinoma, melanoma, non-small cell lung carcinoma, advanced solid tumors of non-germ cell origin	V58.1, E933.1°)
Amifostine (Ethyol) J0207 500 mg	Neurotoxicity, cisplatin-induced (prophylaxis), neuropathy and ototoxicity	(357.6,388.5,389.12,995.2, V58.1, E933.1°)
Amifostine (Ethyol) J0207 500 mg	Reduction in the incidence of murositus in patients receiving radiation therapy or radiation combined with chemotherapy	(l01, 990~ 995.2, V58.0, V58.1)[1]
Amifostine (Ethyol) J0207 500 mg	Reduction in the incidence of xerostomia associated with post-operative radiation treatment of head and neck cancer, where the radiation port includes a substantial portion of the parotid glands	(V58.0, 140._ to 149._, 160._ to 161._, 195.0, 527.7,990) (Please consult your coding manual.)
AminogIutethimide (Cytadren)	ACTH-Producing Tumors	194.0, 194.3, 198.89; 234.8, 227.3,237.0, 162._, 164.0, 157.-> 193
AminogIutethimide (Cytadren)	Adrenal Cortex[1]	194.0
AminogIutethimide (Cytadren)	Breast[1]	174._, 175._
AminogIutethimide (Cytadren)	Prostate[1]	185
Anastrozole (Arimida)	Breast	174._, 175._
Arsenic Trioxide (Trisenox) J9017 1 mg	Acute Myelocytic Leukemia ***	205.0_
Arsenic Trioxide (Trisenox) J9017 1 mg	Acute Promyelocytic Leukemia ***	205.0
Arsenic Trioxide (Trisenox) J9017 1 mg	Chronic Lymphocytic Leukemia ***	204.1_

Arsenic Trioxide (Trisenox) J9017 1 mg	Chronic Myeloid Leukemia ***	205.1_
Arsenic Trioxide (Trisenox) J9017 1 mg	Liver ***	155._
Arsenic Trioxide (Trisenox) J9017 1 mg	Multiple Myeloma ***	203.0_
Arsenic Trioxide (Trisenox) J9017 1 mg	Myelodysplastic Syndromes ***	238.7_
Asparaginase (Elspar, Kidrolase) J9020 10,000 units	Acute Lymphocytic Leukemia	204.0_
Asparaginase (Elspar, Kidrolase) J9020 10,000 units	Acute Nonlymphocytic Leukemia3 (Childhood acute myeloid Leukemia)	205.0_
Asparaginase (Elspar, Kidrolase) J9020 10,000 units	Non-Hodgkin's Lymphomas	200.0_, 200.1_
Azacitidine (Vidaza)	Myelodysplastic Syndromes	238.7
Bexarotene (Targretin)	Cutaneous T-Cell Lymphoma	202.1-, 202.2-, 202.8_
Bicalutamide (Casoda)	Prostate	185
Bleomycin (Blenoxane) J9040 15 units	Cervix	180._
Bleomycin (Blenoxane) J9040 15 units	Esophagus[1]	150._
Bleomycin (Blenoxane) J9040 15 units	Head & Neck	140._ to 149._, 160._, 161._, 195.0
Bleomycin (Blenoxane) J9040 15 units	Hodgkin's Lymphoma	201._
Bleomycin (Blenoxane) J9040 15 units	Kaposi's Sarcoma	176._
Bleomycin (Blenoxane)	Malignant Peritoneal	197.6

J9040 15 units	Effusion[1]	
Bleomycin (Blenoxane) J9040 15 units	Malignant Pleural Effusion	197.2
Bleomycin (Blenoxane) J9040 15 units	Melanoma[1]	172._
Bleomycin (Blenoxane) J9040 15 units	Non-Hodgkin's Lymphomas	200.__, 202.__
Bleomycin (Blenoxane) J9040 15 units	Osteosarcoma[1]	170._, 198.5
Bleomycin (Blenoxane) J9040 15 units	Ovary (germ cell)	183.0, 183.9
Bleomycin (Blenoxane) J9040 15 units	Pancreas***	157._
Bleomycin (Blenoxane) J9040 15 units	Penis	187.1 to 187.4
Bleomycin (Blenoxane) J9040 15 units	Skin	173._
Bleomycin (Blenoxane) J9040 15 units	Soft-Tissue Sarcomas[1]	171._
Bleomycin (Blenoxane) J9040 15 units	Squamous Cell Carcinomas of Skin	173._
Bleomycin (Blenoxane) J9040 15 units	Testes	186._
Bleomycin (Blenoxane) J9040 15 units	Thyroid[1]	193
Bleomycin (Blenoxane) J9040 15 units	Vulva	184.4
Bleomycin (Blenoxane) J9040 15 units	Trophoblastic Neoplasms	236.1
Bortezomib (Ve1cade)	Multiple Myeloma	203.0_

Busulfan (Myleran)	Acute Nonlymphoeytic Leukemia[1]	205.0_
Busulfan (Myleran)	Brain***	191._
Busulfan (Myleran)	Chronic Myelocytic Leukemia	205.1_
Busulfan (Myleran)	Preparative therapy in treatment of malignancies with BMT	
Capecitabine (Xeloda)	Breast	174._, 175._
Capecitabine (Xeloda)	Colorectal	153._, 154._
Carboplatin (ParaplatinParaplatin Solution), J9045 50 mg	Bladder	188._
Carboplatin (ParaplatinParaplatin Solution), J9045 50 mg	Brain	191._
Carboplatin (ParaplatinParaplatin Solution), J9045 50 mg	Breast[l]	174._, 175._
Carboplatin (ParaplatinParaplatin Solution), J9045 50 mg	Carcinoma of unknown primary[l]	199.0, 199.1
Carboplatin (ParaplatinParaplatin Solution), J9045 50 mg	Cervix[3]	180._
Carboplatin (ParaplatinParaplatin Solution), J9045 50 mg	Endometrium[1]	182.0
Carboplatin (ParaplatinParaplatin Solution), J9045 50 mg	Esophagus[1] (also GE junction adenocarcinomas) [1]	150._
Quboplatin (ParapIatinParaplatin Solution), J9045 50 mg	Fallopian tube[1]	183.2
Carboplatin	Head & Neck	140._ to 149._, 160._,

(ParaplatinParaplatin Solution), J9045 50 mg		161._, 195.0
Carboplatin (ParaplatinParaplatin Solution), J9045 50 mg	Hodgkin's Lymphoma[1]	201.__
Carboplatin (ParaplatinParaplatin Solution), J9045 50 mg	Lung	162._
Carboplatin (ParaplatinParaplatin Solution), J9045 50 mg	Melanoma[1]	172._
Carboplatin (ParaplatinParaplatin Solution), J9045 50 mg	Neuroblastoma[3 xx]	160.__ 194._
Carboplatin (ParaplatinParaplatin Solution), J9045 50 mg	Non-Hodgkin's Lymphoma[1]	200.__, 202.__
Carboplatin (ParaplatinParaplatin Solution), J9045 50 mg	Ovary	183.0
Carboplatin (ParaplatinParaplatin Solution), J9045 50 mg	Peritoneal	158,8, 158.9, 197.6
Carboplatin (ParaplatinParaplatin Solution), J9045 50 mg	Retinoblastoma	190.5
Carboplatin (ParaplatinParaplatin Solution), J9045 50 mg	Testes	186._
Carboplatin (ParaplatinParaplatin Solution), J9045 50 mg	Wilms' Tumor[3]	189.0
J9265 30 mg	Bladder	188._
J9265 30 mg	Breast	174._ 175._

J9265 30 mg	Carcinoma of unknown primary[1]	199.0,199.1
J9265 30 mg	Cervix	180._
J9265 30 mg	Endometrial[1]	182.0
J9265 30 mg	Esophagus	150._
J9265 30 mg	Fallopian tube[1]	183.2
J9265 30 mg	Head & Neck	140._ to 149._, 160._, 161._, 195.0
J9265 30 mg	Lung (Non-small cell and small cell)	162._
J9265 30 mg	Kaposi's Sarcoma	176._
J9265 30 mg	Ovary	183.0
J9265 30 mg	Prostate[1]	185
J9265 30 mg	Stomach[1]	151._
J9265 30 mg	Testes[1]	186._
Palonosetron Hydrochloride (Aloxi)[+]	Antiemetic (Chemotherapy-induced)	787.01, 787.03, 995.2
Pamidronate Disodium (Aredia) J2430 30 mg	Hypercalcemia (assoc. with malignancy)	275.42
Pamidronate Disodium (Aredia) J2430 30 mg	Multiple Myeloma with bone metastases	203.0_ and 198.5
Pamidronate Disodium (Aredia) J2430 30 mg	Osteolytic Bone Metastases (with breast cancer/myeloma)	174._, 175._, 198.5
Pamidronate Disodium (Aredia) J2430 30 mg	Paget's Disease of Bone	731.0
Pegaspargase (Oncaspar) J9266 per vial	Acute Lymphocytic Leukemia	204.0
Pemetrexed (Alimta) C9213 10 mg	Lung (non-small cell)[+]	162._

Pemetrexed (Alimta) C9213 10 mg	Mesothelioma[+]	163._
Pentostatin (Nipent) J9268 10 mg	Acute Lymphocytic Leukemia[3]	204._
Pentostatin (Nipent) J9268 10 mg	Chronic Lymphocytic Leukemia[3]	204.1_
Pentostatin (Nipent) J9268 10 mg	Cutaneous T-Cell Lymphoma[1]	202.1_, 202.2_
Pentostatin (Nipent) J9268 10 mg	Hairy Cell Leukemia	202.4_
Pentostatin (Nipent) J9268 10 mg	Prolymphocytic Leukemia	204.9_
Plicamycin (Mithracin) J9270 25 mg	Hypercalcemia (assoc. with malignancy)	275.42
Plicamycin (Mithracin) J9270 25 mg	Hypercalciuria (assoc. with malignancy)	275.40
Plicamycin (Mithracin) J9270 25 mg	Paget's Disease of Bone[1]	731.0
Plicamycin (Mithracin) J9270 25 mg	Testes	186._
Porfimer Sodium (Photofrin)	Esophagus[1]	150._
Porfimer Sodium (Photofrin)	Lung[1]	162._
Prednisone (Deltasone)	Acute Lymphocytic Leukemia	204.0_
Prednisone (Deltasone)	Antiemetic (chemotherapy-induced)	787.01, 787.03, 995.2
Prednisone (Deltasone)	Breast	174._, 175._
Prednisone (Deltasone)	Chronic Lymphocytic Leukemia	204.1_
Prednisone (Deltasone)	Chronic Myleloocytic Leukemia[3]	205.1_
Prednisone (Deltasone)	Hodgkin's Lymphoma	201._

Prednisone (Deltasone)	Hypercalcemia (assoc. with malignancy)	275.42
Prednisone (Deltasone)	Multiple Myeloma[1]	203.0_
Prednisone (Deltasone)	Non-Hodgkin's Lymphomas	200.__, 202.__
Prednisone (Deltasone)	Prostate[1]	185
Prednisone (Deltasone)	Waldenstrom Macroglobulinemia[1]	273.3
Procarbazine (Matulane, Natulan)	Brain	191._
Procarbazine (Matulane, Natulan)	Hodgkin's Lymphoma	201._ _
Procarbazine (Matulane, Natulan)	Lung	162._
Procarbazine (Matulane, Natulan)	Multiple Myeloma[1]	203.00 to 203.01
Procarbazine (Matulane, Natulan)	Non-Hodgkin's Lymphoma	200._ _, 202 _ _
Raltitrexed (Tomudex)	Colorectal[1] (Available in Canada)	153._, 154._
Rituximab (Rituxan) J9310 100 mg	Chronic Lymphocycic Leukemia[1]	204.1_
Rituximab (Rituxan) J9310 100 mg	Immune or Idiopathic Thrombocytopenic Purpura[1]	287.3
Rituximab (Rituxan) J9310 100 mg	Non-Hodgkin's Lymphomas	200._ _, 202._ _
Rituximab (Rituxan) J9310 100 mg	Waldenstrom Macroglobulinemia[1] (also Reinduetion Treatment of Indolent Non-Hodgkin's Lymphomas)[1]	273.3
Sodium Iodide I 131 (Idotope)	Thyroid[1]	193
Sodium Phosphate P 32	Bone Lesions[1]	170._, 198.5

Sodium Phosphate P 32	Chronic Lymphocytic Leukemia[1]	204.1
Sodium Phosphate P 32	Chronic Myelocytic Leukemia[1]	205.1_
Streptozocin (Zanosar) J9320 1 gm	Carcinoid Tumors	152._,153__,154.0,154.1, 162.2 to 162.9. 183.0.259.2
Streptozocin (Zanosar) J9320 1 gm	Colorectal[1]	153._. 154._
Streptozocin (Zanosar) J9320 1 gm	Pancreas	157._
Tamoxifen (NoIvadex)	Breast	174._
Tamoxifen (NoIvadex)	Endometrium[1]	182.0
Tamoxifen (NoIvadex)	Melanoma[1]	172._
Temozolomide (Temodar)	Brain (refractory anaplastic astrocytoma)	191._
Temozolomide (Temodar)	Melanoma[1]	172._
Teniposide (Vumon)	Acute Lympocytic Leukemia	240.0_
Teniposide (Vumon)	Neuroblastoma[1]	160._, 194._
Teniposide (Vumon)	Non-Hodgkin's Lymphomas[1]	200._ _, 202._ _
Testolactone (Teslac)	Breast	174._, 175._
Testosterone	Breast	174._, 175._
Vincristine (Oncovin, Vincasar) J9370 1mg., J9375 2mg., J9380 5g	Rhabdomyosarcoma	171._, 143.9, 158.0, 190.1, 173.9, 174.9, 175.9
Vincristine (Oncovin, Vincasar) J9370 1mg., J9375 2mg., J9380 5g	Soft Tissue Sarcomas	171._
Vincristine (Oncovin, Vincasar) J9370 1mg., J9375 2mg., J9380 5g	Trophoblastic Neoplasms[1]	181, 236.1, 186.9
Vincristine (Oncovin,	Waldenstrom	273.3

Vincasar) J9370 1mg., J9375 2mg., J9380 5g	Macroglobulinemia[1]	
Vincristine (Oncovin, Vincasar) J9370 1mg., J9375 2mg., J9380 5g	Wilms' Tumor	189.0
Vinorelbine Tartrate (Navelbine) J9390 10mg	Breast	174._, 175._
Vinorelbine Tartrate (Navelbine) J9390 10mg	Cervix	180._
Vinorelbine Tartrate (Navelbine) J9390 10mg	Lung (non-small cell)	162._
Vinorelbine Tartrate (Navelbine) J9390 10mg	Ovary[1]	183.0
Zoledronic Acid(Zometa) J3487 1mg	Hypercalcemia (assoc. with malignancy)	275.42
Zoledronic Acid(Zometa) J3487 1mg	Multiple Myeloma	203.0_
Zoledronic Acid(Zometa) J3487 1mg	Bone Metastases from solid tumors, sometimes found with breast carcinoma, multiple myeloma, non-small cell lung carcinoma, renal cell carcinoma, head and neck carcinoma, and prostate carcinoma.[1]	198.5

Generic Drug Index – BIOLOGICAL RESPONSE MODIFIERS AND OTHERS

AGENT	Indication(s)	ICD-9 Code(s)
Aldesleukin (Proleukin) J9015 per single dose vial	Acure Myelogenous Leukemia[1,3]***	205.0_
Aldesleukin (Proleukin) J9015 per single dose vial	Kidney	189.0. 189.1
Aldesleukin (Proleukin) J9015 per single dose vial	Melanoma	172._
Aldesleukin (Proleukin) J9015 per single dose vial	Non-Hodgkin's Lymphoma***	200._ _ • 202._ _
Bacillus Calmette-Guerin (TheraCys, Tice)	Bladder	188._
*Bay 43-9006	Kidney***	189.0, 189.1
Bevacizumabt (Avastin) C9214 10 mg	Colorectal[+]	153._, 154._
Darbepoetin AIfa (Aranesp) J0880* 5 mcgm, Q0137 per 1 mcgm	Anemia of Maligancy[l] Chronic Anemia (Chemotherapy-induced associated with malignancy)1	285.21,285.22,285.9, V58.l°, V66.2°
Darbepoetin AIfa (Aranesp) J0880* 5 mcgm, Q0137 per 1 mcgm	Chronic Illness (renal failure)	*for use in physician office setting only
Denileukin Diftitox (ONTAK)	Cutaneous T-Cell Lymphoma	202.1_, 202.2_
Epoetin Alfa (Procrit, Epogen) Q0136 per 1,000 units	Anemia of Maligancy[l]	
Epoetin Alfa (Procrit, Epogen) Q0136 per 1,000 units	Chemotherapy	V58.1°
Epoetin Alfa (Procrit, Epogen) Q0136 per 1,000 units	Chronic anemia (Chemotherapy-induced associated with malignancy)	285.9
Epoetin Alfa (Procrit, Epogen) Q0136 per 1,000 units	Anemia associated with chronic illness (HIV, renal failure)	285.2_
Epoetin Alfa (Procrit, Epogen) Q0136 per 1,000 units	Myelodysplastic Syndromes	238.7
Epoetin Alfa (Procrit, Epogen) Q0136 per 1,000 units	Reduction of allogeneic blood transfusion in anemic surgery	
Filgrastim (Neupogen) J1440 300 mcgm, J1441 480 mcgm	Acute Myeloid Leukemia	205._ to 208.01
Filgrastim (Neupogen) J1440 300 mcgm, J1441 480 mcgm	Chemotherapy	V66.2° or V58.1 °
Filgrastim (Neupogen) J1440 300 mcgm, J1441 480 mcgm	PBPC Mobilization	
Filgrastim (Neupogen) J1440 300 mcgm, J1441 480 mcgm	Myelodysplastic Syndromes	238.7
Filgrastim (Neupogen) J1440	Neutropenia (Chemotherapy-	288.0

300 mcgm, J1441 480 mcgm	induced, assoc. with bone marrow transplant)	
Gallium Nitrate (Ganite)	Hypercalcemia	275.42
Gemtuzumab Ozogamacin (Mylotarg)	Acute Myeloid Leukemia	205._ to 208.01
Ihritumomab liuxetan (Zevalin)	Non-Hodgkin's Lymphoma	200._ _, 202._ _
Imatinib Mesylate (Gleevec)	Chronic Myelogenous Leukemia	205.1_
Imatinib Mesylate (Gleevec)	Gastrointestinal Stromal Tumors[1]	171.8
Immune Globulin IGIV J1561 500 mg, J1562 5 gm	Bacterial infections (associated with B-Cell chronic lymphocytic leukemia)	790.7
Interferon Alpha-2a (Roferon A) J9213 3 million units	Bladder	188._
Interferon Alpha-2a (Roferon A) J9213 3 million units	Brain	191._
Interferon Alpha-2a (Roferon A) J9213 3 million units	Carcinoid Syndrome	259.2
Interferon Alpha-2a (Roferon A) J9213 3 million units	Chronic Lymphocytic Leukemia[3]	204.1_
Interferon Alpha-2a (Roferon A) J9213 3 million units	Chronic Myelocytic Leukemia	205.1_
Lung (Small and/or Non-Small Cell)	Altretamine,[1] Amifostine, Carboplatin, Cisplatin, Cyclophosphamide, Docetaxel, Doxorubicin, Epirubicin Hydrochloride,1 Etoposide, Etoposide Phosphate, Fluorouracil, Gefitinib, Gemcitabine Hydrochloride, Irinotecan,[1,3] Ifosfamide, Lomustine, Mechlorethamine, Methotrexate, Mitomycin, Paclitaxel, Pemetrexedt , Porfirmer Sodium,[1] Procarbazine, Topotecan, Trimetrexate ***, Uracil Mustard,[3] Vinblastine, Vincristine, Vinorelbine Tartrate	162._
Malignant Peritoneal Effusion	Bleomycin,[1] Chromic Phosphate P32,[1]	197.6

	Mechlorethamine, Thiorepa	
Malignant Pleural Effusion	Bleomycin, Chromic Phosphate P32,[1] Mechlorethamine, Thiotepa	197.2
Melanoma	Aldesleukin, Amifostine, Asparaginase[l] (melanosarcoma), B1eomycin,[1] Carboplatin,[1] Carmustine, Cisplatin, Dacarbazine, Hydroxyurea, Interferon Alpha 2a, 2b, Lomustine,[1] Melphalan, Tamoxifen,[1] Temozolomide,1 Thalidomide[3 xx], Vinblastine, Vincristinel	172._
Mesothelioma	Cisplatin,[3] Pemetrexed[+]	163._
Multiple Myeloma	Arsenic Trioxide ***, Borrezomib, Carmustine, Cyclophosphamide, Dexamethasone,[1] Doxorubicin, Etoposide,[1]Interferon Alpha 2a, 2b, Lomustine,[1] Melphalan, Pamidronate Disodium, Prednisone,[1] Procarbazine,[1] Thalidomide, Vincristine, Zoledronic Acid[l]	203.0_
Myelodysplastic Syndromes	Amifostine,[1]*** Arsenic Trioxide ***, Azacitidine, Cytarabine,[1] Epoetin Alfa, Filgrastim, Sargramostim, Topotecan Hydrochloride[1]	238.7
Neuroblastoma	Cisplatin,[1] Carboplatin,[3 xx] Cyclophosphamide, Dacarbazine,[3] Daunorubicin,[1] Doxorubicin, Etoposide, Ifosfamide,[1] Teniposide,[1] Vinblastine,[1] Vincristine	160. to 194._
Neutropenia	Filgrastim (Chemotherapy·induced, assoc. with bone marrow transplant), Pegfilgrastim, Sargramostim (assoc. with bone marrow transplant, chemotherapy.induced,	288.0

	including chemotherapy assoc.with acute myelogenous leukemia)	
Non-Hodgkin's Lymphoma	Aldesleukin ***, Amifostine, Asparaginase, Bleomycin, Carboplatin,[1] Carmustine, Chlorambucil, Cisplatin, Cladribine, Cyclophosphamide, Cytarabine, Daunorubicin,[1] Dexamethasone,3 Doxorubicin, Epirubicin Hydrochloride,[1] Etoposide, Fludarabine Phosphate, Gemcitabine Hydrochloride[1] , Ibrirumomab tiuxetan, Ifosfamide, Interferon Alpha 2a, 2b, Leucovorin,[1] Mechlorethamine, Mercaptopurine, Methotrexate, Mitoxantrone,[1] Prednisone, Procarbazine, Rituximab, Teniposide,[1] Tositumomab, Iodine 1-131, Uracil Musrard, Vinblastine, Vincristine	200.__, 202.__
Osteosarcoma	Bleomycin, Cisplatin, Cyclophosphamide Dactinomycin, Doxorubicin, Etoposide,[1] Ifosfamide, Leucovorin, Melphalan,[3] Methotrexate, Vincristine, Zoledronic Acid[1]	170._, 198.5 (secondary code)
Ovary	Altretamine,[1] Amifostine, Carboplatin, Chlorambucil, Chromic Phosphate P 32,[1] Cisplatin, Cyclophosphamide, Dactinomycin,[3] Docetaxel,[1] Doxorubicin, Doxorubicin Liposomal, Epirubicin Hydrochloride,[1] Etoposide, Floxuridine, Fluorouracil, Gemcitabine, Hydroxyurea,[1] Ifosfamide, Interferon Alpha 2a, 2b,[3] Melphalan, Methotrexate,1 Pacliraxel, Thalidomide[3 xx],	183.0

	Thiotepa, Topotecan Hydrochloride, Treosulfan,[1] Uracil Mustard,[3] Vinorelbine[l]	
Ovary (Germ Cell)	Bleomycin, Chlorambucil, Cisplatin, Cyclophosphamide, Dactinomycin,[1] Doxorubicin, Doxorubicin Lipsomal,[1] Etoposide,[1] Ifosfamide[l] Vinblastine,[1] Vincristine[l]	183.9
Pancreas	Bleomycin ***, Dacarbazine, Doxorubicin,[1] Fluorouracil, Gemcitabine Hydrochloride, Ifosfamide,[1] Methotrexate,[1] Mitomycin, Oetreotide, Trimecrexate [l] ***	157._
Paget's Disease of Bone	Etidronate, Pamidronate, Plicamycin	731.0
Penis	Bleomycin, Cisplatin[3 xx], FluorouraciI,[1] Methotrexate[l]	187.1 to 187.4
Peritoneal	Carboplatin, [1] Cisplatin, [1] Paclitaxel [1]	158.8, 158.9, 197.6
Prostate	Abarelix, Aminoglutethimide,[l] Bicalutamide, Buserelin,[1] Chlorotrianisene Chromic Phosphate P 32,[1] Cisplatin, Cyclophosphamide, Dexamethasone,[1] Diethylstilbestrol, Docetaxel, Doxorubicin, Estradiol, Estradiol Valerate, Estramustine, Estrogens (Conjugated & Esterified), Estrone, Ethinyl Estradiol, Fluorouracil,[1] Flutamide, Goserelin, Ketoconawle, Leuprolide, Melphalan,[3] Mitoxantrone, Nilutamide,Paclitaxel,[1] Prednisone,[1] Thalidomide[3 xx], Triptorelin Pamoate,[3] Vinblastine[1]	185
Retinoblastoma	Carboplatin, Cisplatin,[1] Cyclophosphamide, Doxorubicin,[1] Etoposide,[1] Vincristine[l]	190.5

Skin	Bleomycin, Cisplatin,[1] Fluorouracil, Interferon Alpha 2a, 2b, Masoprocol, Methoxsalen[1]	173._
Soft-Tissue Sarcomas	Bleomycin,[1] Cisplatin, Cyclophosphamide, Dacarbazine, Dacrinomycin, Daunorubicin,[1] Doxorubicin, Epirubicin Hydrochloride,[1] Etoposide, Ifosfamide, Melphalan,[3] Methotrexare,[1] Vinblastine,[1] Vincristine	171._
Squamous Cell Carcinomas of Skin	Bleomycin	173._

GYNECOLOOIC ONCOLOGY 71, 288-290 (1998)
ARTICLE NO. 00985159

Experience with Platinum-Paclitaxel Chemotherapy in the Initial Management of Papillary Serous Carcinoma of the Peritoneum

Alexander W. Kennedy, M.D., Maurie Markman, M.D., Kenneth D. Webster, M.D., Barbara Kulp, RN, Gert Peterson, RN, Lisa A. Rybicki, M.S., and Jerome L. Belinson, M.D.

Cleveland Clinic Cancer Center and the Departments of Gynecology/Obstetrics and Hematology/Medical Oncology, The Cleveland Clinic Foundation, 9500 Euclid Avenue, Cleveland, Ohio 44195

Received March 23, 1998

Objective. The objective of this study was to assess the activity and toxicity of combination platinum-paclitaxel chemotherapy in the initial management of patients with papillary serous carcinoma of the peritoneum (PSCP).
Methods. Patients initially treated at The Cleveland Clinic Foundation (CCF) for PSCP with platinum-paclitaxel combination chemotherapy regimens were identified and clinical information was abstracted by chart review. Toxicity data, progression-free survival, and overall survival were determined.
Results. Thirty-eight patients (36 Stage mc and 2 Stage IV) were identified. All chemotherapy was administered as outpatient infusions. All patients received paclitaxel (135 or 175 mg/m^2) and 12 received cisplatin and 26 carboplatin. Two hundred thirty-two cycles were administered, with only three (1.3%) episodes of grade 3 toxicity and no grade 4 toxicity. Ninety-two percent of patients experienced at least a 50% reduction in their CA-125 levels and 55% experienced a greater than 90% reduction. Median progression-free survival (Kaplan-Meier) was 15 months and median overall survival was 40 months. Survival for optimally debulked patients (median not yet reached with median follow-up of 24 months) was significantly better than for suboptimally debulked patients (median 32.8 months) (P =0.012).
Conclusion. Platinum-paclitaxel chemotherapy regimens have substantial utility in the initial management of PSCP patients. The toxicity profile is modest. Carboplatin or cisplatin in conjunction with paclitaxel is the current first-line recommended chemotherapy for PSCP.
1998 Academic Press

INTRODUCTION

The clinical features of papillary serous carcinoma of the peritoneum (PSCP) have been described and its similar clinical behavior to papillary serous ovarian cancer has been noted [1-7). The Gynecologic Oncology Group (GOG) has determined pathologic criteria for PSCP and has recently allowed these patients to be entered onto its new epithelial ovarian cancer protocols. Cisplatin-paclitaxel has previously been demonstrated to result in an improved overall response rate and progression-free survival in patients with advanced ovarian cancer compared with cisplatin-cyclophosphamide [8]. Cisplatin-paclitaxel has also been demonstrated to be an active regimen in patients with PSCP [9, 10). We have previously noted an improved toxicity profile and a high response rate with the use of carboplatin-paclitaxel in patients with ovarian carcinoma [11]. We have recently employed this same regimen in patients with PSCP and decided to examine our results using platinum-paclitaxel chemotherapy in the initial management of patients with this disease.

MATERIALS AND METHODS

The Cleveland Clinic gynecologic tumor registry was used to identify patients treated at the Cleveland Clinic Foundation (CCF) for PSCP with platinum-paclitaxel chemotherapy regimens from January 1, 1993 through July 1, 1997. The majority of patients received their initial surgery as well as all chemotherapy

entirely at the CCF although patients operated on at other institutions were included if all operative reports and pathology materials were available for review. All patients received chemotherapy under the direction of CCF physicians in The Gynecology Oncology Treatment Center.

PSCP, consistent with GOG criteria, was defined as (1) diffuse intraperitoneal high-grade papillary serous or anaplastic adenocarcinoma, (2) small ovaries with surface involvement with or without minimal cortical involvement or no ovarian involvement at all and usually associated with (3) elevations in serum CA-125 levels. Clinical records were abstracted for standard demographic information and toxicity data (GOG criteria), as well as progression-free and overall survival. Data management and analysis was performed using the SAS statistical package. The Kaplan-Meier method was used to estimate survival and progression-free survival. The log-rank test was used to compare overall and progression-free survival between optimally and suboptimally debulked patients. All statistical tests were performed using $P < 0.05$ to indicate statistical significance.

RESULTS

Thirty-eight patients were identified who received platinum-paclitaxel regimens as first-line adjuvant chemotherapy following surgery for PSCP. Their mean age was 62 years (range 39-78 years). Thirty-six were FIGO Stage mc and two were FIGO Stage IV. Thirteen patients were optimally debulked (greatest residual tumor diameter $\leq$ 1 cm) and 25 were suboptimally debulked. Twelve initially received cisplatin 75 mg/m2 rapid infusion and 26 received carboplatin (AUC4 9, AUC5 11, and AUC6 6) as a 30-min infusion. Paclitaxel was administered as a 3-h outpatient infusion (135 mg/m2 in 9 patients and 175 mg/m2 in 29 patients). Two hundred thirty-two cycles of combination chemotherapy were administered. Only 3 patients, all of whom received cisplatin-paclitaxel, experienced an episode of grade 3 toxicity (two episodes of neutropenia and one episode of vomiting) and 110 patients experienced grade 4 toxicity.

Based on clinical, radiologic, and serologic testing, 26 patients had a complete response, 7 a partial response, 3 stable disease, and 2 progressive disease. Thirty-five (92%) patients had a >50% reduction in prechemotherapy baseline CA-125 levels and 21 (55%) had a >90% reduction. The overall group had a median progression-free survival of 15 months and a median survival of 40 months. Median progression-free survival (median follow-up 24 months, range 8-53 months) for optimally debulked patients was 16.8 months compared with 12.4 months for suboptimally debulked patients (median follow-up 16 months, range 1-41 months) ($P = 0.19$). Median survival for optimal patients has not been reached yet compared with 32.8 months for suboptimal patients ($P = 0.02$).

Five additional patients were identified who received cisplatin (one patient) or carboplatin (four patients) along with paclitaxel as neoadjuvant chemotherapy for presumed PSCP. These patients all had elevated CA-125 levels, cytologic evidence from peritoneal or pleural fluid of high-grade adenocarcinoma, and no evidence of an ovarian mass on CT scanning. Neoadjuvant chemotherapy was selected due to their poor overall status and high likelihood for severe operative complications. Two patients had a complete clinical response, two had a partial response, and one had progressive disease. Four had a >50% reduction in baseline CA-125 levels and two had a >90% reduction. Median progression-free survival (median follow-up 8 months, range 1-32 months) was 12.7 months and median survival was also estimated to be 12.7 months.

DISCUSSION

Platinum and paclitaxel combination chemotherapy regimens have significant activity and an acceptable toxicity profile in the initial management of PSCP. We have demonstrated marked activity of these regimens, with the majority of patients (92%) demonstrating a greater than 50% reduction in baseline CA-125 levels and 55% demonstrating a greater than 90% decline. Likewise, the majority of patients achieved either a complete (68%) or partial (18%) clinical response.

The current study patients had an estimated median progression-free survival of 15 months and an estimated median survival of 40 months. This survival is consistently longer than what has been reported in

previous studies employing cisplatin combination regimens for PSCP patients prior to the advent of paclitaxel: 31.5 months [2], 17 months [3], 20 months [4], 19 months [5], 20 months [6], 21 months [7], 21.5 months [10], and 11.3 months [12]. The consistent and marked superiority in survival for the current study patients who received paclitaxel with cisplatin or carboplatin suggests that paclitaxel is improving the survival of patients with PSCP.

As is the case in most reports, the percentage of patients with PSCP who achieved optimal debulking status with initial surgery in the present series is low (34%). Compared with the GOG study of McGuire *et at.* [8] employing cisplatin and paclitaxel in suboptimally debulked epithelial ovarian cancer patients, the suboptimally debulked PSCP patients achieved an estimated progression-free survival of 12.4 months (vs 17.9 months) and an estimated survival of 32.8 months (vs 37.5 months). While the survival results for our patients are somewhat inferior, they do approach the results in ovarian cancer patients and suggest a similar utility of platinum-paclitaxel regiments in PSCP patients.

The platinum and paclitaxel regimens employed in the present study have a very acceptable rate of serious toxicity (1% grade 3 and 0% grade 4 in 232 cycles). There was no grade 3 or 4 toxicity in patients receiving carboplatin-paclitaxel. This has been demonstrated to be an acceptable regimen for patients, similar to our prior experience in other gynecologic malignancies' [11]. Patients also appreciate that these regimens are administered on an outpatient basis and do not require hospitalization.

The current results also support the use of platinum-paclitaxel regimens in a neoadjuvant mode in two clinical settings suggesting probable underlying PSCP. First, in patients severely medically compromised with cytologically positive ascites or pleural fluid and a marked increased CA-125, primary chemotherapy might be employed to avoid assorted operative risks and there is a reasonable expectation for a response. Second, in a similar patient without severe medical problems, who, based on CT scanning or physical findings, has bulky disease so extensive that optimal debulking is highly unlikely to be achieved [13], neoadjuvant chemotherapy could be considered.

In conclusion, platinum-paclitaxel regimens have substantial activity in the management of PSCP. Similar to their use in papillary serous adenocarcinoma of the ovary, a high response rate is observed with an acceptable toxicity profile. Based on current information, combination carboplatin-paclitaxel or cisplatin-paclitaxel is the chemotherapy regimen of first choice in PSCP

REFERENCES

1. Mills SE, Anderson WA, Fechner RE, Austin MB: Serous surface papillary carcinoma: A clinico-pathologic study of 10 cases and comparison with stage III-IV ovarian serous carcinoma. Am J Surg Pathol 12:827834, 1988

2. Fromm GL, Gershenson DM, Silva EG: Papillary serous carcinoma of the peritoneum. Obstet Gynecol 75:89-95, 1990

3. Ransom DT, Patel SR, Keeney GL, Markasian GD, Edmonson JH: Papillary serous carcinoma of the peritoneum: A review of 33 cases treated with platin based chemotherapy. Cancer 66:1091-1094, 1990

4. Bloss ID, Liao SY, Buller RE, Manetta A, Berman ML, McMeekin S, Bloss LP, DiSaia PI: Extraovarian peritoneal serous papillary carcinoma: A case-control retrospective comparison to papillary adenocarcinoma of the ovary. Gynecol Oncol 50:347-351, 1993

5. Killackey MA, Davis AR: Papillary serous carcinoma of the peritoneal surface: Matched-case comparison with papillary serous ovarian carcinoma. Gyneco1 Onco1 51:171-174,1993

6. Fowler JM, Nieberg RK, Schooler TA, Berek IS: Peritoneal adenocarcinoma (serous) of mullerian origin: A subgroup of women presenting with peritoneal carcinomatosis. Int 1 Gyneco1 Cancer 4:43-51, 1994

7. Ben-Baruch G, Sivan E, Moran 0, Rizel S, Menczer 1, Siedman DS: Primary peritoneal serous papillary carcinoma: A study of 25 cases and comparison with stage III-IV ovarian papillary serous carcinoma. Gynecol Oncol 60:393-396, 1996

8. McGuire WP, Hoskins WJ, Brady MF, Kucera PR, Partridge EE, Look KY, Clarke-Pearson DL, Davidson M: Cyclophosphamide and cisplatin compared with paclitaxel and cisplatin in patients with stage III and stage IV ovarian cancer. N Engl J Med 334:1-6, 1996

9. Menzin AW, Aikins JK, Wheeler IE, Rubin SC: Surgically documented responses to paclitaxel and cisplatin in patients with primary peritoneal carcinoma Gynecol Oncol 62:55-58, 1996

10. Piver MS, Eltabbakh GH, Hempling RE, Recio OF, Blumenson LE: Two sequential studies for primary peritoneal carcinoma: Induction with weekly cisplatin followed by 'either cisplatin-doxorubicin-cyclophosphamide or paclitaxel-cisplatin. Gynecol Oncol 67:141-146, 1997

11. Markman M, Kennedy A, Webster K, Kulp B, Peterson G, Belinson J: Carboplatin plus paclitaxel in the treatment of gynecologic malignancies: The Cleveland Clinic experience. Semin Oncol 24:S15-26-S15-29, 1997

12. Dalrymple JC, Bannatyne P, Solomon HJ, Tattersall MH, Atkinson K, Carter J, Duval P, Elliott P, Friedlander M: Extraovarian peritoneal serous papillary carcinoma: A clinicopathologic study of 31 cases. Cancer 64: 110-115, 1989

13. Meyer J, Kennedy AW, Friedman R, Ayoub A, Zepp RC: CT predicted outcome of cytoreductive surgery for ovarian carcinoma. Radiology 165: 875-878, 1995

Abdom Imaging 24:78-81 (1999)

Abdominal
Imaging
Springer-Vering New York Inc. 1999

Peritoneal serous papillary carcinoma: radiological appearance

T. Furukawa, [1] J. Ueda, [1] S. Takahashi, [1] K. Higashino, [l] K. Shimura, [2] T. Tsujimura, [3]/ Y. Araki[4]
[1]Department of Radiology, Sumitomo Hospital, 5-2-2 NaklInoshima, Kim-kll, Osaka 530-0005, Japan
[2]Department of Gynecology and Obstetrics, SlImitomo Hospital, 5-2-2 Nakanoshima, Kim-1m, Osaka 530-0005, Japan
[3]Department of Pathology, Sumitomo Hospital, 5-2-2 Nakanoshima, Kim-ku, Osaka *53Q..OOOS,* Japan
[4]Department of Radiology, Kinki University School {]f Medicine. 377-2, Ohno-higashi, Osaka-Sayama 589-0014, Japan

Received: 12 November 1997/Accepted: 31 December 1997

Abstract
Background: The radiological appearance of peritoneal serous papillary carcinoma (PSPC) is described.
Methods: Three cases of PSPC were analyzed retrospectively with regard to the radiological appearance and histopathological features.
Results: All three patients were women, aged 44-71 years. Massive ascites and a greater omentum tumor were observed on computed tomography in all patients. Double-contrast enema performed in one patient showed irregularity on the upper aspect of the transverse colon. Radiological examinations excluded primary tumors in both gastrointestinal and genital organs in all patients. Histological diagnosis was made from the surgical specimen in two patients and from an autopsy specimen in one patient. All patients had a large omental tumor involving the transverse colon, but the ovaries were not involved or only minimally involved on the surface. Serum CAl25 was markedly elevated, and immunohistochemical staining for CAl25 was positive within the tumor cell cytoplasm in all three patients.
Conclusion: PSPC cannot be diagnosed from radiological findings alone because of its similarity to metastatic peritoneal carcinomatosis and peritoneal mesothelioma. Marked elevation of serum CAl25 may help with PSPC diagnosis. Response to treatment is promising, and exploratory laparotomy is thus justified when a patient shows characteristic radiological findings and high CAl25 level.

Since 1959, when Swerdlow reported the first case of peritoneal serous papillary carcinoma (PSPC) as a "mesothelioma resembling papillary ovarian adenocarcinoma" [1], PSPC has become recognized as an independent pathological entity. The etiology of PSPC is uncertain but it is believed to be a primary peritoneal tumor arising from the secondary Mullerian system in the mesothelium. The histopathological features of this tumor are identical to those of ovarian papillary serous carcinoma (OPSC), but in PSPC the ovaries are intact or only their surface is affected [2]. The clinical features of PSPC are also similar to those of peritoneal carcinomatosis due to opse and the response to using cisplatin-based chemotherapy regimen is favorable. Thus, a correct diagnosis of PSPC, distinguishing it from the other peritoneal malignancies with a poor prognosis, is required before treatment. There are few descriptions of the radiological appearance of PSPC in the literature; therefore, we analyzed the radiological, clinical, and histopathological features of this carcinoma in our institution.

Key words: Peritoneum-Neoplasm-Computed tomography-
Barium enerna -CA125.

* *Present address:* Department of Radiology, Osaka University Medical School, 2-2 Yamada-oka, Suila, Osaka 565-0871, Japan
Correspondence to: T. Furukawa

Case reports

Case 1

A 59-year-old woman presented with rapidly progressing abdominal distention and loss of appetite. She had a history of chronic thyroiditis for 25 years, but the thyroid function had normalized during that period. Physical examination showed diffuse goiter, massive ascites, and palpable induration in the lower abdomen. Cytological examination of ascetic fluid showed adenocarcinoma cells, which did not stain with periodic acid-Schiff with diastase digestion. Serum carbohydrate antigen 12-5 (CAI25) was markedly elevated to 11,100 *IU/mL* (normal < 35 *IU/mL).* Computed tomography (CT) demonstrated a poorly demarcated smudgy tumor in front of the transverse colon (Fig. 1A), but no involvement of the genital organs was observed. Double-contrast enema showed irregularity on the upper aspect of the transverse colon (Fig. 1B). This finding suggests colon involvement through the gastrocolic ligament, which is typically seen in an advanced gastric cancer [31. but no abnormality was detected in the stomach on endoscopic and double-contrast examination. Because there was no evidence of a primary site in the gastrointestinal system, an ovarian tumor was suspected. After one course of chemotherapy using cisplatin, bilateral adnexectomy was performed and a peritoneal infusion catheter was implanted. At surgery, a large omental tumor involving the transverse colon was found, and multiple nodules were seen to be scattered on the peritoneum and on the surface of the ovaries. Histopathological examination of surgical specimens of the tumor demonstrated a tubulopapillary structure of the tumor cells with considerable nuclear atypism and psammoma bodies (Fig. 1C). On immunohistochemical staining, the tumor cells were found to be positive for CAI25. As a result, PSPC was diagnosed. The patient received chemotherapy postoperatively, by both intravenous and intraperitoneal infusion, with a cisplatin-based regimen. The intraperitoneal tumors then disappeared, and she has been free of disease for 4 years.

Case 2

A 44-year-old woman visited our clinic having suffered from abdominal distention for I month. Physical examination showed a large amount of ascites, and cytological examination of ascitic fluid showed adenocarcinoma cells. On ultrasonography, there was a vague tumor echo in the peritoneal space surrounded by massive ascites. CT also showed ascites and an omental tumor but no other abnormality (Fig. 2). Because serum CAl25 was elevated to 3,598 JU/mL, an ovarian tumor could not be excluded. Exploratory lapurotomy was then performed. At surgery, there was a huge omentallumor involving the colon, but the ovaries could not be observed, being obscured by diffuse adhesive carcinomatosis. Despite chemotherupy, the patient died 110 days after surgery and autopsy was performed. Mucroscopically, there was minimal invasion of the ovarian cortex and of the fallopian tubes bilaterally. Light microscopic examination of the tumor cells demonstrated a tubulopapillary structure, and immunohistochemical staining showed CA125-positive cells. These macroscopic and microscopic findings were thus consistent with n diagnosis of PSPC.

Case 3

A 71-year-old woman was admitted to our hospital with rapidly progressive abdominal distention. Massive ascites was found on physical examination, and adenocilrcinoma cells were detected in the ascitic fluid. Serum CA125 was extremely elevated to 10,329 IU/mL. A gynecological survey, including ultrasonography, did not show any neoplastic lesion in the genital organs. One week after admission, induration was felt on palpation in the left lower abdomen. Abdominal CT showed a ·poorly defined hazy mass in the anterior portion of the peritoneal cavity, together with retroperitoneal lymphadenopathy and

ascites (Fig. 3). Although no definitive diagnosis was obtained, intraperitoneal infusion of cisplatin was started. The ascites was then diminished, and the serum CAl25 level fell to 7124 IU/mL.

Sixty-six days after admission, the patient complained of sudden abdominal pain. On abdominal radiography, free air was observed intraperitoneally. At surgery, the transverse colon was obstructed by an omental tumor, and perforation at the cecum was observed. Multiple nodules were found on the peritoneum, but a primary tumor of the genital organs was excluded macroscopically. The affected transverse colon was resected, but its mucosa was free of disease. Microscopically, no neoplastic lesion was found in the biopsied ovaries and a histological survey of the tumor demonstrated papillary serous carcinoma with CA I25-positive cells. The diagnosis, based on surgical and pathological findings, was PSPC.

Discussion

Neoplasms of the female peritoneum are classified into three groups: mesothelial, Mullerian, and metas~ atic [4]. Embryologically, the germinal epithelium of the ovary and the mesothelium of the peritoneal cavity derive from the same coelomic epithelium [5]. PSPC belongs to Mullerian tumors, arising from the mesothelium and with a capacity to differentiate the second Mullerian system, located external to the cavities of the original Mullerian ducts. The histopathological features of PSPC are identical to those of OSPC, but in PSPC the ovaries are intact or only the surface of the ovaries is affected. The biological behavior of PSPC is also similar to that of OSPC. Three cases of PSPC with long-term survival have been reported by Chen and Flam (6], and our patient 1 has survived for 4 years. Strnad et al. reported five patients with complete response to cisplatin-based chemotherapy and recommended therapeutic guidelines for advanced ovarian carcinoma, including initial surgical cytoreduction followed by cisplatin-based ombination chemotherapy (7]. In view of good response, it is crucial to recognize PSPC and differentiate it from other peritoneal tumors with poor a prognosis, such as peritoneal carcinomatosis originating from sources other than ovarian cancer or malignant mesothelioma.
.
The clinical and pathological features of PSPC have been clarified, but there are few descriptions of its imaging features in the literature. In our cases, three characteristic CT findings were noted: a large amount of ascitic fluid, a greater omentum tumor, and exclusion of primary tumor in both the gastrointestinal system and the genital organs. However, these findings do not seem to be specific to PSPC. Walkey et al. described CT findings in patients *with* peritonea! carcinomatosis; the most common feature was ascites, and the most common origin of the carcinomatosis was ovarian [8]. They found that the detectability of the primary site was only about 40-50%. In addition, the greater omentum was the· favored site for peritoneal seeding. The primary sites in their patients with omental *caking* differed considerably and included the ovary, fallopian tube, colon, stomach, and peritoneum.

Peritoneril mesothelioma *is* another type of primary peritoneal tumor. It has some histopathological variants, and Fox classified *it* into four groups: cystic mesothelioma, well-differentiated papillary mesothelioma, fibrous mesothelioma, and diffuse mesothelioma [4]. The CT findings in mesothelioma differ greatly and include peritoneal thickening, nodular apperance of the peritoneum, omental caking, different amount of ascites, and so on [9 - 11]. Occasionally, the CT appearance of peritoneal mesothelioma is similar to that of our PSPC, making it difficult to differentiate these two tumors.

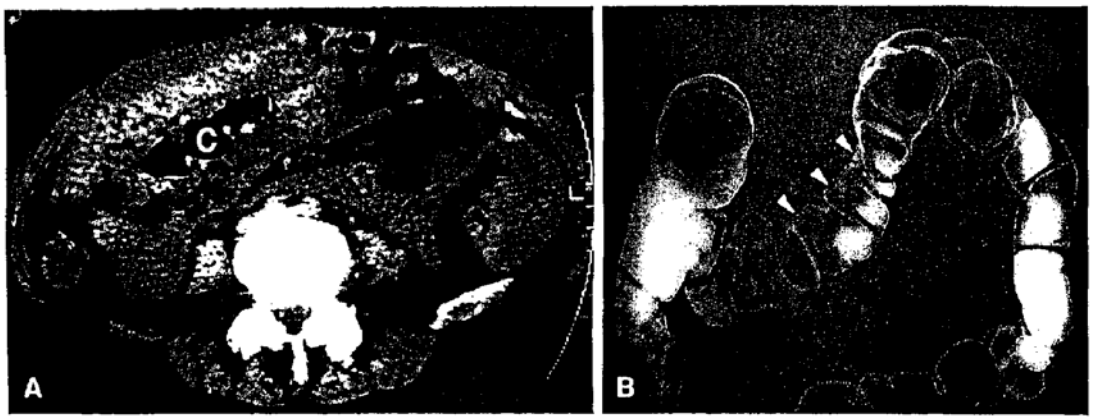



Fig. 1. Case I. A CT of the lower abdomen demonstrates ascites (A) and a smudgy omental tumor *(arrowheads)* located in front of the transverse colon (C). The contour of the tumor is poorly demarcated. and the tumor is attached to the transverse colon_ Except for the omental tumor, no primary tumor is shown. B Double-contrast enema shows irregularity on the upper aspect of the transverse colon *(arrowheads).* This finding suggests colon involvement through the gastrocolic ligament. C Photomicrograph of petitoneal serous papillary carcinoma. Hematoxylin & eosin stain; original magnification x20. A tubulopapillary structure with nuclear atypism and psammoma bodies (ps) is demonstrated.

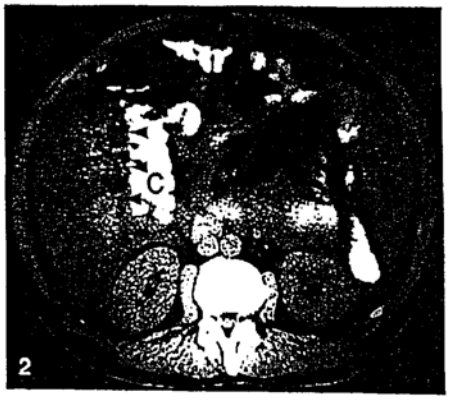

Fig. 2. Case 2. CT at the level of kidney shows a poorly demarcated tumor *(arrowheads)* surrounded by fat density adjacent to the colon (C). No primary site in another location is detected. The peritoneal cavity is occupied by ascites (A).

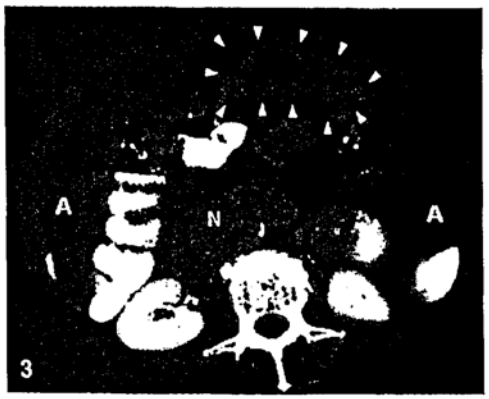

Fig. 3. Case 3. CT lit the level of the kidney with contrast administration. A poorly defined hazy mass *(arrowheads)* is located in the anterior portion of the peritoneal cavity, in which massive ascites *(A)* is collected. Retroperitoneal lymphadenopathy is also demonstrated *(N).* but the gastrointestinal system and genital organs appear free from disease.

Cooper et al. analyzed the radiographic appearances of benign and metasatic malignant omental disease [12]. They identified four distinct patterns: omental caking, finely infiltrated fat with a "smudged appearance," cystic masses, and discrete nodules. The CT appearances of the omental lesion in our cases differed somewhat; case I showed a "'smudged appearance" and cases 2 and 3 showed omental caking. Because both patterns are common in metastatic disease, it is difficult to differentiate PSPC from metastatic peritoneal carcinomatosis.

In case 1 double-contrast enema demonstrated involvement of the superior part of the transverse colon. This finding implies invasion in the area between the taenia omentalis and the taenia mesocolica [3]. This area easily becomes involved by extension of malignancy through the gastrocolic ligament, as is commonly seen in cases of gastric cancer. However, if the greater omentum is attached to the transverse colon at the taenia omentalis, primary omental disease could also extend to the same portion of the colon. The radiological findings on CT and double-contrast enema in our PSPC patients were indistinguishable from those in metastatic peritoneal carcinomatosis or peritoneal mesothelioma; therefore, we conclude that PSPC cannot be diagnosed on radiological grounds alone.

CA125 is a useful marker for epithelial ovarian cancer. In our cases, the serum CA125 levels were extremely elevated. to values ranging between 3598 and more than 10,000 IU/mL. A case of PSPC with a high CA125 level has been reported by Rosen et a1. [13]. Bast et a1. measured CA125 levels in patients with epithelial ovarian carcinoma and in different control groups [14] and found a value of more than 2000 *IU/mL* only in epithelial ovarian carcinoma. If a patient with peritoneal carcinomatosis had such a high level of CA125, epithelial ovarian malignancy was usually suspected. Therefore, in combination with exclusion of ovarian malignancy on radiological examination,' findings of an extremely high level of CA125 and characteristic CT features such as ascites and omental tumor give strong reasons to suspect PSPC, and exploratory laparotomy should be undertaken for a definitive diagnosis.

Because the biological behavior of PSPC is supposed to be similar to that of OSPC, multidisciplinary management with cell reduction surgery and chemotherapy I which are applied for stage III and IV ovarian carcinoma, would appear to be the optimal treatment of PSPC. In case 1, combination chemotherapy using intravenous and intraperitoneal infusion of anticancer drugs was used in addition to surgery. This treatment has been effective for 4 years. In cases 2 and 3, the prognoses were poor; intensive chemotherapy was not possible because of poor general condition. On the assumption that the therapeutic strategy in PSPC should be same as that in advanced ovarian cancer, an aggressive approach to PSPC is desirable.

With the recent advances in cancer treatment, the prognosis of PSPC has been improved. Radiological examinations, including CT. and serum CA125 measurement are recommended in patients with suspected PSPC to arrive at a precise diagnosis.

References

1. Swerdlow M. Mesothelioma of the pelvic peritoneum resembling papillary cystadenocarcinoma of the ovary. *Am J Obstet Gynecol* 1959;77:197-200
2. Dalrymple JC, Bannatyne P, Russell P, et al. Extraovarian peritoneal serous papillary carcinoma: a clinicopathologic study of 31 cases. *Cancer* 1989:64: 110-115
3. Meyers MA. The colon: normal and pathologic analomy. In: *Dynamic radiology of the abdomen.* New York: Springer Verlag, 1988:387-422
4. Fox H. Primary neoplasia of the female peritoneum. *Histopathology* 1993;23: 103-110
5. Lauehlan SC. The secondary Milerian system, *Obstet Gynecol Surv 1972;27:133-146*
6. Chen KTK. Flam MS. Peritoneal papillary serous carcinoma with long-term survival. *Cancer* 1986;58: 1371-1373
7. Strnad CM. Grosh WW, Baxter J, et al. Peritoneal carcinomatosis of unknown primary site in women. *Ann lntern Med* 1989;111:213-217
8. Walkey MM, Friedman AC, Sohotra P, et al. CT manifestation of peritoneal carcinomatosis. *AJR* 1988:150: 1035-1041
9. Whitley NO, Brenner DE, Antman KH, et al. CT of peritoneal mesothelioma: analysis of eight cases. *AJR* 1982: 138:531 -535
10. Reuter L. Raptpoulos V, Krolikowski FJ, et al. Diagnosis of peritoneal mesothelioma. *AJR 1983;140:1189-1194*
11. Smith T, Malignant peritoneal mesothelioma: marked variability of CT findings. *Abdom Imaging 1994;19:27-29*
12. Cooper C, Jeffrey RB, Siverman PM. et al. Computed tomography of omental pathology. *JCAT 1986;10:62-66*
13. Rosen HR. Preiser ACR, Stierer M. et al. Non-ovarian peritoneal papillary serous carcinoma with high CA125 levels. *Arch Gynecol Obstet* 1991;25: 199-202
14. Bast RC. Klug T, John ES, et al, A radioimmunoassay using a monoclonal antibody to monitor the course of epithelial ovarian cancer. *N Engl J Med 1983;309:883-887*

Journal of Surgical Oncology 1998;68:173-178

Peritoneal Papillary Serous Carcinoma: Study of 15 Cases and Comparison With Stage III-IV Ovarian Papillary Serous Carcinoma

BENJAMIN PIURA, MD, FRCOG, [1] MIHAI MEIROVITZ, MD, [1] MARY BARTFELD, MD, [1]
ILANA YANAI-INBAR, MD, [2] AND YORAM COHEN, MD, [3]
[1] *Unit of Gynecologic Oncology, Department of Obstetrics and Gynecology, Soroka Medical Center and Faculty of Health Sciences, Ben-Gurion University of the Negev, Beer-Sheva, Israel*
[2] *1nstitute of Pathology, Soroka Medical Center and Faculty of Health Sciences, Ben-Gurion University of the Negev, Beer-Sheva, Israel*
[3] *1nstitute of Oncology, Soroka Medical Center and Faculty of Health Sciences, Ben-Gurion University of the Negev, Beer-Sheva, Israel*

Background and Objectives: Peritoneal papillary serous carcinoma (PPSC) is histologically and clinically similar to stage III-IV ovarian papillary serous carcinoma (OPSC). The purpose of this study was to investigate the clinical findings, treatment, and outcome of PPSC patients compared with stage III-IV OPSC patients.
Methods: Data from the files of 15 PPSC patients and 52 stage III-IV OPSC patients who were managed at the Soroka Medical Center between January 1991 and December 1997 were evaluated.
Results: With regard to patients' characteristics, presenting signs and symptoms, type and extent of surgery, tumor response to first-line chemotherapy, recurrence-free interval, recurrence site, tumor response to second-line chemotherapy, and serum CA-J25 levels, no significant differences were observed between the PPSC patients and the stage III-IV OPSC controls. The prevailing presenting symptoms were abdominal mass and ascites. The mainstay of treatment was debulking surgery followed by adjuvant platinum-containing chemotherapy. The objective response rate to first-line chemotherapy was 80%. The actuarial 5-year survival rate for the PPSC patients and stage III-IV OPSC patients was 52.0% and 20.5%, respectively ($0.05 < P < 0.1$).
Conclusions: The clinical and surgical characteristics of patients with PPSC are similar to those of patients with stage III-IV OPSC. When treatment strategies for stage III-IV OPSC are applied to PPSC, the survival of PPSC patients may be similar or even better than that of stage III-IV OPSC patients
J. Surg. Oneol. /998;68:173-178. © 1998 Wi1ey-Liss. Inc.

KEY WORDS: papillary serous carcinoma; debulking surgery; staging; chemotherapy; survival

INTRODUCTION

The Mullerian papillary serous carcinomas form a spectrum of tumors composed of peritoneal papillary serous carcinoma (PPSC), ovarian papillary serous carcinoma (OPSC), and uterine papillary serous carcinoma (UPSC). These tumors, despite the differences in their site of origin, have similar histologic and clinical features. OPSC is the most common and best recognized Mullerian papillary serous carcinoma, whereas PPSC is a relatively uncommon tumor that accounts for 7-21% of all epithelial ovarian carcinomas [1-5]. The adoption of the International Federation of Gynecology and Obstetrics (FlGO) staging of epithelial ovarian carcinoma for use in PPSC has presented a problem, since from the start PPSC is an intra-abdominal disease that must be regarded as at least stage III. Thus, when a study is designed to compare PPSC patients with OPSC controls, the OPSC controls should be patients with stage III-IV disease. Management of PPSC has followed that of epithelial ovarian carcinoma with initial debulking surgery (total abdominal hysterectomy, bilateral salpingooophorectomy, omentectomy, and extirpation of all respectable tumor masses) followed by adjuvant platinumcontaining chemotherapy as the mainstay of

treatment. The Soroka Medical Center (SMC) in Beer-Sheva is the only tertiary care medical facility in the south of Israel that provides hospital care for a population of 500,000: Jews from various ethnic origins make up 80% of the population and Arab-Bedouins make up the remaining 20%. The aim of the present study was to assess the clinical and histologic findings, treatment, and outcome of 15 patients with PPSC compared with 52 patients with stage III-IV OPSC managed at the SMC over a 7-year period.

MATERIALS AND METHODS

The clinical and pathological records of 15 PPSC patients and 52 stage III-IV OPSC patients who were managed between January 1991 and December 1997 at SMC, Beer-Sheva, Israel, were reviewed.

The pathologic diagnosis of PPSC was based on the following Gynecologic Oncology Group's (GOG's) inclusionary criteria for PPSC [6]: (1) both ovaries must be either physiologically normal in size or enlarged by a benign process; (2) the involvement in the extraovarian sites must be greater than the involvement on the surface of either ovary; (3) microscopically, the ovarian component must be one of the following: (a) nonexistent, (b) confined to ovarian surface epithelium with no evidence of cortical invasion, (c) involving ovarian surface epithelium and underlying cortical stroma but with any given tumor size less than 5 x 5 mm, (d) tumor less than 5 x 5 mm within ovarian substance associated with or without surface disease; and (4) the histological and cytological characteristics of the tumor must be predominantly of the serous type that is similar or identical to OPSC, any grade.

Treatment for both PPSC and OPSC usually included initial surgical debulking followed by adjuvant systemic chemotherapy. Sometimes, if the patient was considered not feasible for initial surgery, she had an interval surgery after a few cycles of neoadjuvant chemotherapy. Surgical debulking and staging usually consisted of peritoneal washings or collection of ascites if present, scrapings of the undersurfaces of the diaphragm, resection of tumor masses, total abdominal hysterectomy, bilateral salpingo-oophorectomy, omentectomy, peritoneal and serosal biopsies, and sampling of paraaortic and pelvic lymph nodes. In all patients at initial laparotomy, an attempt was made to debulk the tumor load as much as possible. Surgical debulking was considered "optimal" if at the end of surgery the largest residual tumor mass left in the abdominal cavity was less than I cm in its largest diameter. Although there is no official surgical staging system for PPSC, all cases of PPSC were considered to be the equivalent of FlGO stage III or IV ovarian cancer.

After surgery, patients were generally treated with intravenous platinum-based combination chemotherapy. The most prevailing chemotherapy regimen for both PPSC and OPSC consisted of cisplatin 75 mg/m^2 and cyclophosphamide 750 mg/m^2 at 3-week intervals. None of the patients received radiotherapy. Postoperatively, during and after treatment with chemotherapy, the patients were monitored with serial determinations of serum CA-125, and periodic ultrasound and computerized tomographic examinations. None of the patients had second-look laparotomy. Recurrent disease was documented in patients in whom serum CA-125 levels returned to normal and who were free of disease after initial surgery and then, during or after first-line chemotherapy, demonstrated rising levels of serum CA-125 and/or developed evidence of recurrent tumor in either the abdomen and/or pelvis or elsewhere.

The PPSC patients were compared to the OPSC patients with regard to age at initial diagnosis, menstrual history, parity, ethnic origin, past medical history, use of hormone replacement therapy, family history of cancer, presenting signs and symptoms, type and extent of surgery, stage of disease, type and response to first-line chemotherapy, recurrence-free interval, recurrence sites, type and response to second-line chemotherapy, serum CA-125 levels, and results of follow-up.

Evaluation of statistical significance of the difference between means was performed by the Student (-test [7]. Difference in the frequency of observations was evaluated by the X^2 test and in a 4-fold table by the X^2 test with Yates correction (X^2y) for small numbers [7]. Survival was calculated using the Kaplan-Meier method [8] and compared statistically using the log-rank test [9].

RESULTS

The clinical characteristics of the two groups of patients are detailed in Table I. The differences between the PPSC and OPSC patients with regard to mean age at diagnosis, menarche and menopause, parity, and ethnic origin were not significant. The ovaries and/or uterus had not been previously removed in any of the 15 PPSC patients, whereas in 5/52 (9.6%) OPSC patients the uterus had been previously removed. Two of 15 (13.3%) PPSC patients and 7/52 (13.5%) OPSC patients had received estrogen replacement therapy. None of the patients in the two groups had either a metachronously or synchronously second primary malignancy. A family history of cancer was obtained in 2/15 (13.3%) PPSC (1 breast cancer and 1 endometrial carcinoma) and 11/52 (21.2%) OPSC patients (3 breast cancer, 3 ovarian carcinoma, 2 gastric cancer, 1 endometrial carcinoma, 1 uterine cervix carcinoma, and 1 liver carcinoma).

TABLE I. Clinical Characteristics of PPSC and OPSC Patients*

Characteristics	PPSC (n = 15)	OPSC (n = 52)
Mean age (years) at Diagnosis [a]	62.0	55.6
Mean age (years) at Menarche [b]	12.3	11.0
Mean age (years) at Menopause [c]	50.6	48.0
Mean No. of children [d]	2.4	2.7
Ethnic origin [e] Ashkenazi Jewish	9 (60.0%)	38 (73.1%)
Ethnic origin [e] Sephardic Jewish	5 (33.3%)	13 (25.0%)
Ethnic origin [e] Arab-Bedouin	1 (6.7%)	--
Ethnic origin [e] Unknown	--	1 (1.9%)
Use of HRT [f] Estrogen + progesterone	1 (6.7%)	3 (5.8%)
Use of HRT [f] Estrogen alone	1 (6.7%)	4 (7.7%)
Use of HRT [f] None	13 (86.7%)	45 (86.5%)

*HRT = hormone replacement therapy; PPSC, peritoneal papillary serous carcinoma; OPSC, ovarian papillary serous carcinoma

[a] t = 0.538; DF = 65; $0.5 < P < 0.6$ [not significant (NS)].

[b] t = 1.137; DF = 65; $0.2 < P < 0.3$ (NS).

[c] $t = 0.436$; DF = 65; $0.6 < P < 0.7$ (NS).

[d] t = 1.000; DF = 65; $0.3 < P < 0.4$ (NS).

[e] $x^2 = 6.788$; DF = 3; $0.05 < P < 0.1$ (NS).

[f] $\mathbf{x}^2y = 0.1968$; DF = 1; $0.5 < P < 0.75$ (NS).

The presenting signs and symptoms are displayed in Table II. In both groups, the most prevailing presenting signs and symptoms were abdominal mass and ascites.

The surgical characteristics of the two groups of patients are detailed in Table III. With regard to type and extent of surgery, the differences between the PPSC and OPSC patients were not statistically significant. In the PPSC group, the ovaries were involved with tumor in 12/15 (80%) patients and were tumor-free in 3/15 (20%) patients. The FIGO staging of the tumor in the two groups of patients is presented in Table IV.

TABLE II. Presenting Signs and Symptoms of PPSC and OPSC Patients·

Sign/Symptom	PPSC (n = 15)	OPSC (n = 52)
Abdominal mass [a]	15 (100.0%)	41 (78.8%)
Ascites [b]	9 (60.0%)	20 (38.5%)
Pleural effusion [c]	2 (13.3%)	6 (11.5%)
Nausea [d]	1 (6.7%)	5 (9.6%)
Vomiting [e]	1 (6.7%)	5 (9.6%)
Constipation [f] Estrogen + progesterone	2 (13.3%)	2 (3.8%)

*Some patients presented with a combination of signs and symptoms; therefore, percentage adds up to >100%.
[a] $x^2y = 2.4112$; DF = I; $0.1 < P < 0.25$ [not significant (NS)].
[b] $x^2y = 1.3938$; DF = I; $0.1 < P < 0.25$ (NS).
[c] $x^2y = 0.0692$; DF = I; $0.75 < P < 0.9$ (NS).
[d] $x^2y = 0.7491$; DF = I; $0.25 < P < 0.5$ (NS).
[e] $x^2y = 0.7491$; DF = I; $0.25 < P < 0.5$ (NS).
[f] $x^2y = 0.5591$; DF = I; $0.25 < P < 0.5$ (NS).

TABLE III. Surgical Characteristics of PPSC and OPSC Patients

Characteristics	PPSC (n = 15)	OPSC (n = 52)
Type of surgery [a] Primary	13 (86.7%)	44 (8.6%)
Type of surgery [a] Interval	2 (13.3%)	8 (15.4%)
Extent of surgery [b] Optimal	10 (66.7%)	27 (51.9%)
Extent of surgery [b] Non-optimal	3 (20.0%)	17 (32.7%)
Extent of surgery [b] Palliative	2 (13.3%)	8 (15.4%)

[a] $x^2y = 0.0461$; DF = 1; $0.75 < P < 0.9$ [not significant (NS»).
[b] $x^2 = 1.1190$; DF = 2; $0.5 < P < 0.75$ (NS).

TABLE IV. FIGO Staging of PPSC and OPSC Patients*

FIGO stage	PPSC (n = 15)	OPSC (n = 52)
IIIB	--	2 (3.8%)
IIIC	12 (80.0%)	39 (75.0%)
IV	3 (20.0%)	11 (21.2%)

* $x^2 = 0.625$; DF = 2; 0.5 <P<0.75 (not significant)

Primary chemotherapy and the patients' responses to primary chemotherapy are described in Table V. The differences between the PPSC and OPSC groups with regard to type of first-line chemotherapy, number of cycles of chemotherapy, and response to cisplatin-based chemotherapy were not statistically significant. Objective response to first-line cisp1atin-containing chemotherapy was observed in 12/15 (80%) PPSC and 4l/52 (78.8%) OPSC patients, whereas 3/l5 (20%) PPSC and 1l/52 (21.2%) OPSC patients were refractory to cisp1atin-containing chemotherapy. Of the patients who enjoyed a complete response to primary therapy, a recurrence-free interval of more than 6 months was observed in 3/11 (27.3%) PPSC and 16/31 (51.6%) OPSC patients ($X_2y = 3.0484$; DF = 1; $0.05 < P < 0.1$). The most common recurrence sites in both groups were the abdomen and pelvis. Second-line chemotherapy utilizing agents such as cisplatin. carboplatin, paclitaxe1, etoposide, (VP-16), cyclophosphamide, and hexamethylmelamine was employed in 10/15 (66.7%) PPSC and 23/52 (44.2%) OPSC patients ($X_2y = 1.5328$; DF = 1; $0.1 < P < 0.25$). Objective response to second-line chemotherapy was observed in 2/10 (20%) PPSC and 8/23 (34.8%) OPSC patients ($X_2y = 1.5908$; DF = 1; $0.1 < P < 0.25$).

Serum CA-125 at the time of diagnosis ranged from zero to 4,078 U/ml (mean: 827.5 U/*ml)* and from zero to *3,896 U/ml* (mean: 462.8 *Vlm1)* in the PPSC and OPSC groups, respectively (t = 1.066; DF = 65; $0.2 < P < 0.3$). At the completion of first-line chemotherapy it ranged from zero to 50 U/*ml* (mean: 13.3 U/*ml)* and from zero to 4,522 U/*ml* (mean: 146 U/*ml)* in the PPSC and OPSC groups, respectively (t = 1.066; DF = 65; $0.1 < P < 0.2$).

Follow-up of the PPSC patients ranged from 1 to 77 months, with 8/15 (53.3%) patients followed for at least 5 years or until time of death. Follow-up of the OPSC patients ranged from 1 to 105 months, with *36/52* (69.2%) patients followed for at least 5 years or until time of death. Of the PPSC patients, *3/15* (20%) were alive free of disease, 7/15 (46.7%) were alive with disease, and *5/15* (33.3%) had died of disease. Of the OPSC patients, *11/52* (21.2%) were alive free of disease, *6/52* (11.5%) were alive with disease, 1/52 (1.9%) had died of intercurrent disease, and *34/52* (65.4%) had died of disease. The difference between the two groups in the proportion of patients who either were alive with disease or had died of disease was not statistically significant *[121* 15 (80%) PPSC patients vs. *40/52* (76.9%) OPSC patients; $X_2Y = 0.01$; DF = 1; $0.975 < P < 1.0$]. However, the difference between the two groups in the proportion of patients who were alive with disease was statistically significant *[7/15* (46.7%) PPSC patients vs. 6/52 (11.5%) OPSC patients; $X_2y = 7.077$; DF = I; $0.001 < P < 0.0$ 1]. Overall, the actuarial 5-year survival rate for the PPSC patients was 52.0% and that for the stage III-IV OPSC patients was 20.5% ($0.05 < P < 0.1$) (Fig. 1).

TABLE V. Type of First-Line Chemotherapy, Number of Cycles, and Response to First-Line Chemotherapy in PPSC and OPSC Patients*

First-line chemotherapy	PPSC (n = 15)	OPSC (n = 52)
Type [a] CAP	– –	4 (7.7%)
Type [a] CP	11 (73.3%)	41 (78.8%)
Type [a] TP	4 (26.7%)	7 (13.5%)

Mean No. of cycles [b]	7.5	7.0
Response [c] Complete response	11 (73.3%)	31 (59.6%)
Response [c] Partial response	1 (6.7%)	10 (19.2%)
Response [c] Stable disease	1 (6.7%)	– –
Response [c] Progress of disease	2 (13.3%)	11 (21.2%)

*CAP = Cyclophosphamide, doxorubicin, and cisplatin; CP = cyclophosphamide and cisplatin; TP = paclitaxel and cisplatin.
[a] $x^2 = 2.45$; OF = 2; $0.25 < P < 0.5$ [not significant (NS)].
[b] t = 0.520; OF = 65; $0.6 < P < 0.7$ (NS).
[c] $x^2 = 5.3772$; OF = 3; $0.1 < P < 0.25$ (NS).

DISCUSSION

PPSC was first described by Swerdlow [10] as malignant mesothelioma in 1959. Very soon it has become apparent that with regard to histology, immunohistochemistry, cellular ultrastructure, epidemiology, and clinical behavior, PPSC is not distinguishable from OPSC and therefore should not be considered a malignant mesothelioma but a variant of OPSC [3-5,11,12]. Some authors [13] have not even considered PPSC as a different clinical entity from OPSC and therefore have not reported it separately from stage III-IV OPSC, whereas others [3,14,15] have considered PPSC to be a different clinical entity from OPSC and have reported it separately from OPSC.

We, like others [6,12], could not demonstrate significant differences between PPSC and stage III-IV OPSC patients with regard to patients' characteristics, presenting signs and symptoms, type and extent of surgery, tumor response to first-line chemotherapy, recurrence-free interval, recurrence site, tumor response to second-line chemotherapy, and serum CA-125 level. Like others [12], we have observed that the rate of successful debulking and the result of postoperative aggressive treatment with platinum-based combination chemotherapy were the same in both groups. Some authors [16], however, have reported a lower rate of optimal cytoreduction and decreased response to platinum-based chemotherapy in the PPSC group. The literature is conflicting regarding the relative survival in these two patient groups. Some authors [5,13,16 have reported a poorer survival for patients with PPSC compared to patients with OPSC, whereas others [17,18] could not find a significant difference in the survival between patients with PPSC and patients with OPSC. We have observed a better 5-year survival rate for the PPSC patients (52%) compared to the stage III-IV OPSC patients (20.5%), but the difference is only of borderline significance ($P < 0.1$). Moreover, we have noticed that although almost the same proportion of patients in each group either were alive with disease or had died of disease (80% vs. 76.9%, respectively), a significantly greater proportion of PPSC patients (46.7%) compared to OPSC patients (11.5%) were alive with disease. Thus, in this series, it seems that the PPSCs progressed more slowly and caused death over a more extended period of time than did the OPSCs.

The finding that the presently reported 15 PPSCs accounted for 22.4% of all stage III-IV intra-abdominal Mullerian papillary serous carcinomas seen during the study period corroborates previous studies that demonstrated that PPSC account for about one-fifth of all intra-abdominal Mullerian papillary serous carcinomas 0-5]. Although Arab-Bedouins make up 20% of the population in the south of Israel, we have observed that only 1/15 (6.7%) PPSC patients and none of the OPSC patients was an Arab-Bedouin woman. Although Jews of Asian-African origin

(Sephardic) make up 60% of the Jewish population in the south of Israel, we have noticed more women of European-American origin (Ashkenazi) than those of Asian-African origin (Sephardic) affected by PPSC and OPSC.

Like others [1,2, I2, 19], we have observed that the mean age at diagnosis of the PPSC and OPSC patients was about 60 years. The prevailing presenting symptoms of both PPSC and OPSC patients were abdominal mass and ascites. The finding in this study that 20% of the PPSC patients presented with stage IV disease does not exactly corroborate previous studies that demonstrated a greater proportion (28-32%) of PPSC patients with stage IV disease [2,11,16].

In contrast to some authors [20] who have shown that the ovaries were free of tumor in 7-14% of PPSC patients, we have found that the ovaries were free of tumor in 20% of the PPSC patients. Sometimes, because of extensive confluent spread of the tumor, it is difficult to identify during surgery and even on pathological examination whether the tumor distribution is consistent with extraovarian (PPSC) or ovarian (OPSC) origin. In this series, however, we did not encounter such a case.

Obviously, prophylactic bilateral oophorectomy prevents the development of OPSC, but cannot prevent the development of PPSC [2 1,22]. This raises doubts about the value of prophylactic oophorectomy at routine hysterectomy and in patients with familial ovarian cancer syndrome in totally preventing intra-abdominal Mullerian carcinomatosis [11,12,22]. Clinicians should explain to patients undergoing bilateral oophorectomy that although the risk of developing intra-abdominal Mullerian carcinomatosis is reduced (to approximately one-fifth of what it would have been had the ovaries been retained), it is not totally abolished since papillary serous carcinoma may arise de novo from the peritoneal surfaces. In this series, however, none of the patients with PPSC had a previous bilateral oophorectomy.

In conclusion, this study indicates that with regard to patients' clinical and surgical characteristics, PPSC is similar to stage III-IV OPSC. It has been observed that the survival of PPSC patients was better than that of stage III-IV OPSC patients, but the difference is of borderline significance *(P* < 0.1). Nevertheless, the overall survival is low, but it is not unexpected in view of the advanced stage of disease.

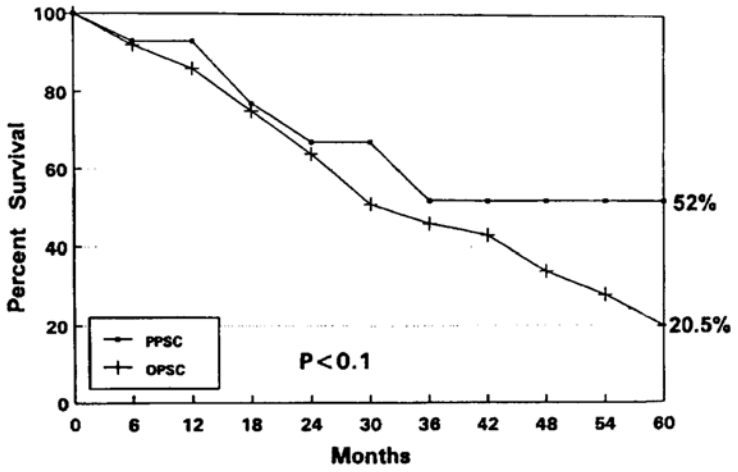

Fig. 1. Actuarial survival of PPSC and OPSC patients.

REFERENCES

1. Fowler *1M.* Nieberg RK, Schooler TA, et. a1: Peritoneal adenocarcinoma (serous) of MUllerian type: A subgroup of women presenting with peritoneal carcinomatosis. Int J Gynecol Cancer 1994;4:43-51.
2. Altaras MM, Aviram R, Cohen I, et a1.: Primary peritoneal papillary serous adenocarcinoma: Clinical and management aspects. Gynecol Oncol 1991;40:230-236.
3. Fromm GL, Gershenson OM, Silva EG: Papillary serous carcinoma of the peritoneum. Obstet Gynecol 1990;75:89-95.
4. Feuer GA, Shevchuk M, Calanog A: Normal-sized ovary carcinoma syndrome. Obstet Gynecol 1989;73:786-792.
5. Mills SE, Andersen WA, Fechner RE, et a1.: Serous surface papillary carcinoma. A clinicopathologic study of 10 cases and comparison with stage III-IV ovarian serous carcinoma. Am J Surg Pathol 1988; 12:827-834.
6. Bloss JO, Liao SY, Buller RE, et a1.: Extraovarian peritoneal serous papillary carcinoma: A case-control retrospective comparison to papillary adenocarcinoma of the ovary. Gynecol Oncol 1993;50:347-351.
7. Swinscow TOV: "Statistics at Square One." London: British Medical Association, 1983.
8. Kaplan EL, Meier P: Non-parametric estimation from incomplete observations. J Am Stat Assoc 1958;53:457--481.
9. Peto R, Pike MC, Armitage P, et al.: Oesign and analysis of randomized clinical trials requiring prolonged observation of each patient. II. Analysis and examples. Br J Cancer 1977;35:1-39.
10. Swerdlow M: Mesothelioma of the pelvic peritoneum resembling **178 Piura et al.** papillary cystadenocarcinoma of the ovary: Case report. Am J Obstet Gynecol 1959;77:197-200.
11. Dalrymple JC. Bannatyne p. Russell P, et al.: Extraovarian peritoneal serous papillary carcinoma. A clinicopathologic study of 31 cases. Cancer 1989;64:110-115.
12. Ben-Baruch G, Sivan E. Moran 0, et al.: Primary peritoneal serous papillary carcinoma: A study of 25 cases and comparison with stage III-IV ovarian papillary serous carcinoma. Gynecol Oncol 1996;60:393-396.
13. Gooneratne S, Sassone M. Blaustein A, et al.: Serous surface papillary carcinoma of the ovary: A clinicopathologic study of 16 cases. Int J Gynecol Pathol 1982;1:258-269.
14. Strnad CM, Grosh WW. Baxter J, et al.: Peritoneal carcinomatosis of unknown primary site in women. A distinctive subset of adenocarcinoma. Ann Intern Med 1989;111 :213-217.
15. Fox H: Primary neoplasia of the female peritoneum. Histopathology 1993;23:103-110.
16. Killackey MA, Davis AR: Papillary serous carcinoma of the peritoneal surface: Matched-ease comparison with papillary serou, ovarian carcinoma. Gynecol Oncol 1993;51 :171-174.
17. Chen KT, Flam MS: Peritoneal papillary serous carcinoma with long-term survival. Cancer 1986;58: 1371-1373.
18. Le1e SB, Piver MS, Matharu J. et al.: Peritoneal papillary carcinoma. Gynecol OncoI1988;31:315-320.
19. Ransom DT, Patel SR, Keeney GL, et al.: Papillary serous carcinoma of the peritoneum. A review of 33 case, treated with platinbased chemotherapy. Cancer 1990;66:1091-1094.
20. Russell P, Bannatyne PM, Solomon HJ, et al.: Multifocaltumorigenesis in the upper genital tract. Implications for staging and management. Int J Gynecol Pathol 1985;4: 192-210.
21. Chen KT, Schooley JL. Flam MS: Peritoneal carcinomatosis after prophylactic oophorectomy in familial ovarian cancer syndrome. Obstet Gynecol 1985;66(Suppl):93S-94S.
22. Tobacman IK, Greene MH, Tucker MA. et al.: Intra-abdominal carcinomatosis after prophylactic oophorectomy in ovarian cancer-prone families. Lancet 1982;2:795-797.

Peritoneal Cancer

Last Updated: February 28, 2003

Synonyms and related keywords: primary peritoneal cancer, peritoneal malignancy, peritoneum, peritoneal carcinoma, peritoneal carcinoma, malignant mesothelioma, benign papillary mesothelioma, desmoplastic small round cell tumor, peritoneal angiosarcoma, leiomyomatosis peritonealis disseminata, LPD, peritoneal hemangiomatosis, abdominal therapeutic radiation, radiation therapy, asbestos exposure

Author: Daniel Efiom-Ekaha, MD, Fellow in Hematology/Oncology, Department of Internal Medicine, State University of New York Downstate

Education
Coauthor(s): Arunbhai G Patel, MD, Chief, Department of Internal Medicine, Division of Hematology-Oncology, Brooklyn Hospital Center;
Adekunle Kuku, MD, Staff Physician, Department of Internal Medicine, Brooklyn Hospital Center
Daniel Efiom-Ekaha, MD, is a member of the following medical societies: American Cancer Society

Editor(s): Robert C Shepard, MD, FACP, Associate Professor of Medicine and Surgery, University of Virginia, Medical Officer, Division of Clinical Trial Design and Analysis, Office of Therapeutics Research and Review, Center for Biologics Evaluation and Research, FDA;
Francisco Talavera, PharmD, PhD, Senior Pharmacy Editor, Pharmacy, eMedicine;
Benjamin Movsas, MD, Vice-Chairman, Department of Radiation Oncology, Fox Chase Cancer Center;
Rajalaxmi McKenna, MD, FACP, Southwest Medical Consultants, SC, Department of Medicine, Good Samaritan Hospital, Advocate Health Systems; and John S Macdonald, MD, Medical Director, Saint Vincent's Comprehensive Cancer Center; Chief, Division of Medical Oncology, Professor, Department of Internal Medicine, New York Medical College

Background: Since the early years of the last century, the peritoneum has been a topic of considerable interest. Initially, the major focus was on peritoneal infections;

however, with the subsequent introduction of antibiotics, the focus of gynecological and nongynecological pathologists shifted to neoplastic and nonneoplastic peritoneal conditions.

Currently, a number of primary cancers have been described to originate from the peritoneum. Knowledge of primary peritoneal cancers is important because these entities have been implicated in many cases of carcinomas of unknown primary origin when no clear explanation for peritoneal carcinomatosis can be documented. The existence of this phenomenon also explains the occurrence of ovarian cancer in women several years after bilateral oophorectomy, as is observed with primary peritoneal carcinoma. Other described primary peritoneal cancers and tumorlike lesions include malignant mesothelioma, benign papillary mesothelioma, desmoplastic small round cell tumors, peritoneal angiosarcoma, leiomyomatosis peritonealis disseminata (LPD), and peritoneal hemangiomatosis.

Pathophysiology: The peritoneum is a serous lining of mesothelial cells with a rich vascular and lymphatic capillary network.

Peritoneal mesothelioma is a primary tumor of the mesothelial lining of the peritoneum. The tumor can be classified as benign, borderline malignant, or malignant. Benign mesothelioma is a circumscribed papillary tumor of considerable firmness, while malignant mesothelioma covers the surface of the mesentery and can obliterate the entire peritoneal cavity.

Both mesotheliomas (solitary and diffuse forms) have a similar growth pattern and are composed of strands of connective tissue covered by cells that react positively to periodic acid-Schiff staining in the cytoplasm. These cells grow in multiple layers, forming papillary or tubular formations. In most instances, the tumor is dominated by growth of cells, but very rarely, abundant production of collagen fibers can occur, leading to the fibrous type of peritoneal mesothelioma. Microscopic findings in malignant mesothelioma include extensive cell vacuolization, rare psammoma bodies, the presence of hyaluronic acid, and a lack of mucin.

This tumor tends to spread into the pleural space, leading to pleural plaques observed on chest x-ray films in 50% of patients with primary peritoneal cancer, compared to 20% of patients with primary pleural mesothelioma, which suggests a higher level of asbestos exposure in patients with peritoneal disease. The incidence of asbestos exposure in patients with benign mesothelioma approximates the incidence rate of exposure in the general population, while the association of malignant peritoneal mesothelioma and asbestos exposure has been reported to be as high as 83%. Malignant peritoneal mesothelioma has also been associated with abdominal therapeutic radiation.

A rare syndrome of recurrent peritoneal mesothelial cysts (also termed benign cystic peritoneal mesothelioma) consisting of multiloculated inclusion cysts has been described. Some authors advocate classifying this lesion as reactive proliferation rather than malignancy.

Primary peritoneal carcinoma (also termed serous surface papillary carcinoma) is a malignancy that arises primarily from peritoneal cells. The mesothelium of the peritoneum and the germinal epithelium of the ovary arise from the same embryologic origin; therefore, the peritoneum may retain the multipotentiality of the mullerian system, allowing the development of a primary carcinoma.

A desmoplastic small round cell tumor can sometimes be difficult to differentiate from a malignant peritoneal mesothelioma. This tumor demonstrates extensive involvement of the peritoneal surfaces, with rapid multifocal growth and hematogenous metastasis to the liver, lungs, and lymph nodes.

LPD is a condition of small, firm, white-to-gray nodules studding and covering the peritoneal surface. Histologically, these nodules are composed mainly of smooth muscle cells with variable amounts of decidualization and hyalinization. Minimal mitotic activity is observed, with no evidence of atypia or nuclear pleomorphism. The histogenesis of LPD has been a point of debate because of the discrepancy of ultrastructural studies. Regardless of whether the cellular content is decidual cells or smooth muscle cells, embryogenesis involves multipotential mesenchymal stem cells. Excessive hormonal stimulation with estrogen or progesterone has been recognized as a potential stimulus for LPD development. Although once believed to be an unquestionably benign process, cases have been reported of patients with LPD that subsequently evolved into aggressive leiomyosarcomas.

Peritoneal angiosarcomas are rare tumors that appear benign histologically but usually act aggressively. They may arise following previous radiation treatment to the serous membranes. Hemangiomatoses of the peritoneum are rare and are usually associated with hemangiomas of the GI tract or cutaneous hemangiomas.

Frequency:

- In the US: Primary peritoneal carcinoma is a rare tumor occurring almost exclusively in women. Peritoneal mesotheliomas are also rare, with 2 cases per 1 million population reported each year. However, the incidence appears to be increasing. Based on the prior use of asbestos, more than 8 million persons in the United States are exposed and at risk. Benign cystic peritoneal mesotheliomas are rare.

Mortality/Morbidity:

- Survival rates are poor for patients with primary peritoneal carcinoma, with 100% mortality; the median survival reported is from 12-25 months, even with extensive surgery and chemotherapy.
- Benign cystic peritoneal mesotheliomas are associated with prolonged survival despite bulky disease.
- Desmoplastic small round cell tumors are associated with a reported median survival of 17 months.

Sex:

• Primary peritoneal carcinoma is a rare tumor occurring almost exclusively in women.
• Malignant mesotheliomas show extreme male predominance (93% in one series).

Age: Patients with primary peritoneal carcinoma are older compared to those with epithelial ovarian cancers.

• Desmoplastic small round cell tumors occur in adolescent persons and young men.
• Benign cystic peritoneal mesotheliomas are rare and are found predominantly in younger women.
• Most cases of LPD have been discovered in reproductive-aged women (mean age 37 y), in young pregnant women, and in women who have hormonal excess for any other reason. In most reported cases, nodules either regress or exhibit growth once the hormonal stimulation has been removed.

History:

• Primary peritoneal carcinoma usually manifests with abdominal distention and diffuse nonspecific abdominal pain secondary to ascites. This tumor is described almost exclusively in women. Atypical presentations of primary peritoneal carcinoma have been described, including a case of severe glandular dysplasia on a screening Papanicolaou test (Pap smear), which, after ectocervical biopsy, revealed evidence of moderately differentiated adenocarcinoma, later confirmed to be metastasis of primary peritoneal carcinoma.

• Malignant peritoneal mesothelioma usually manifests with symptoms and signs of advanced disease, including pain, ascites, weight loss, or an abdominal mass.

- These tumors tend to manifest with diffuse involvement of the peritoneal cavity, including omental caking and diaphragmatic and pelvic tumor deposits.
- Thrombocytosis is common and is associated with a poor prognosis.
- Other common clotting abnormalities include phlebitis, emboli, hemolytic anemia, and disseminated intravascular coagulation.
- Esophageal achalasia, secondary amyloidosis, and dermatomyositis have been reported.
- Most patients die without metastasis or involvement of the chest.

• Desmoplastic small round cell tumors are rare, typically occurring in adolescent persons and young men and manifesting with extensive involvement of the peritoneal surfaces. Rapid multifocal growth and hematogenous metastasis to the liver, lungs, and lymph nodes are common.

• LPD is found most commonly in women of reproductive age who are pregnant; these patients are usually asymptomatic, have a long-term history of oral contraceptive use, or have uterine leiomyomas at the time of diagnosis. All cases of this disease have been discovered intraoperatively during obstetric and gynecologic surgical procedures.

• Peritoneal hemangiomas are usually associated with hemangiomas of the GI tract. They are rare and can manifest with ascites, anemia (from chronic blood loss), thrombocytopenia, and coagulopathy.

Causes:

• A chromosomal translocation, which results in the fusion of the Ewing sarcoma gene with the Wilms tumor gene, has been identified and implicated in desmoplastic small round cell tumors.
• Hereditary predisposition may playa role in primary peritoneal carcinoma because patients with the *BRCA*1 mutation have an increased risk.
• Although conventional wisdom dictates that asbestos is the environmental factor most commonly associated with mesothelioma, asbestos does not transform human mesothelial cells in tissue culture. This suggests that additional carcinogens act in concert with asbestos to cause mesothelioma.

Ovarian Cysts

Other Problems to be Considered:

The differential diagnosis of primary peritoneal cancers includes peritoneal metastasis (ie, peritoneal carcinomatosis) from primary sites including the GI tract, ovaries, or breast or as part of the syndrome of adenocarcinomas of unknown primary site. Although the primary histology findings dictate the clinical course, important concepts of diagnosis and treatment are common to all forms. The most important risk factor for developing peritoneal carcinomatosis is the depth of invasion of the primary tumor.

• Granulomatous lesions

- Vernix caseosa and meconium peritonitis
- Granulomatous peritonitis secondary to foreign material, including keratin
- Necrotic pseudoxanthomatous nodules
- Postcautery granulomas

• Nongranulomatous histiocytic lesions

- Ceroid-rich histiocytic infiltrates
- Peritoneal melanosis
- Mucicarminophilic histiocytosis
- Other histiocytic infiltrates

• Fibrosing lesions

- Sclerosing peritonitis
- Peritoneal fibrosis nodules

• Mesothelial lesions
- Mesothelial hyperplasia
- Peritoneal inclusion cysts

Pseudomyxoma peritonei typically includes any low-grade or benign tumor within the abdominal cavity that produces copious amounts of mucinous ascites. This condition includes peritoneal spread from welldifferentiated adenocarcinomas of the GI tract and benign mucinsecreting adenomas of the appendix.

Lab Studies:

• Malignant peritoneal mesothelioma: Findings from cytologic examination of ascites can suggest the diagnosis, and findings from percutaneous biopsy of the omentum can help verify the diagnosis. This condition is usually confined to the abdomen at the time of diagnosis.

Imaging Studies:
• Standard imaging tests, including ultrasonography and helical CT scans, are notably insensitive for the detection of peritoneal tumors.

- The sensitivity of CT scans for peritoneal nodules measuring smaller than 1 cm is approximately 15-30%.
- Ultrasonography is similarly insensitive; therefore, considering findings, rather than solid tumor detection, that may suggest the presence of peritoneal lesions is important. These include the presence of ascites, fixing together of bowel loops, thickening of mesentery, and omental matting.

• CT scan findings are nonspecific in primary papillary serous carcinoma of the peritoneum. Consider this diagnosis when findings include ascites, omental caking, and diffuse enhancement with nodular thickening of the parietal peritoneum of the pelvis observed with normal-sized ovaries, with or without a fine enhancing surface nodularity of the ovary.
• Some studies show that MRI is superior to helical CT scan for the detection of peritoneal and bowel wall abnormalities.
• Positron emission tomography imaging has not been shown to be sensitive for lesions smaller than 1 cm in the abdominal cavity.
• Findings from radionuclide scan studies can help confirm the diagnosis of peritoneal hemangiomas; the isotope concentrates in the area where platelets are being sequestered. A CT scan and ultrasound also may detect larger hemangiomas. Angiographic evaluation is a more precise, although invasive, procedure when radionuclide scans, CT scan, and ultrasound findings are negative.

Procedures:

• Procedures for the workup of peritoneal lesions include peritoneal lavage cytology. This can be performed using a cutaneous closed technique or at the time of laparoscopy or laparotomy. The sensitivity of the test results depends on the ability to completely lavage all regions of the peritoneal cavity and the ability to detect cancer cells being shed into the peritoneal cavity by the tumor.

• Direct visualization of the peritoneal surfaces along with palpation of the abdominal contents is by far the most sensitive modality for detecting peritoneal cancer. This can be accomplished with a minimally invasive approach (ie, laparoscopy), which allows for safe, directed peritoneal lavage for cytology and with open abdominal exploration and palpation of the peritoneal surfaces. Open abdominal exploration and palpation are extremely sensitive for 1- to 2-mm peritoneal nodules.

Histologic Findings: Primary peritoneal carcinoma is histologically indistinguishable from primary epithelial ovarian carcinoma; however, primary ovarian cancer can be excluded based on certain criteria. First, both ovaries must be of normal in size. Second, the extraovarian involvement must be greater than the involvement on the surface of the ovary. Third, the ovarian component must be smaller than 5 by 5 mm within the ovary or confined to the ovarian surface. Finally, the cytologic characteristics must be of the serous type.

Medical Care:

• In general, primary peritoneal carcinoma is treated similar to ovarian cancer, with cytoreduction and adjuvant therapy with platinum-based chemotherapeutic regimens. Treatment consists of total abdominal hysterectomy and bilateral salpingooophorectomy as needed, with debulking of the tumor and follow-up chemotherapy. Carboplatin or cisplatin therapy, in combination with paclitaxel, is associated with a high response rate and improvement of median survival.

• Chemotherapy and radiation therapy are used sometimes and may cause a partial response. Intraperitoneal instillation of radioactive colloidal gold Au 198 has been reported to improve symptoms of peritoneal mesothelioma. In one study, intraperitoneal chemotherapy using cisplatin with intravenous thiosulphate protection resulted in a 59% complete response rate. Other agents used intraperitoneally include mitomycin C, doxorubicin, and epidoxorubicin.

• Benign papillary mesothelioma is believed to require only follow-up care after excisional biopsy because no malignant potential has been reported.

• Excessive hormonal stimulation appears to correlate with LPD development because it is commonly associated with pregnancy. Conservative management, with removal of the source of excessive hormones where applicable, and long-term follow-up care are recommended because of the general indolent clinical course of LPD.

• Treatment of peritoneal and GI hemangiomas has involved surgical removal. Radiation therapy has also been reported effective in some cases but applies mostly to single, large hemangiomas. Corticosteroids have also been successful in many cases; recently, trials with the fibrinolytic inhibitor epsilon-aminocaproic acid, which promotes local thrombosis within the hemangioma, have been reported. Chemotherapy with cyclophosphamide has also been used in children with hemangiomas, with variable success. The use of a carbon dioxide laser may be a useful adjunct to surgery when diffuse capillary hemangiomas are present and not amenable to surgical extirpation.

Surgical Care:
• Treatment of primary peritoneal carcinoma consists of total abdominal hysterectomy and bilateral salpingo-oophorectomy as needed, with debulking of tumor and follow-up chemotherapy

• Treatment of malignant peritoneal mesothelioma consists primarily of surgical palliation. Complete surgical resection is rarely, if ever, feasible and has not been shown to afford a survival benefit in the absence of additional therapy. If laparoscopy is used to help make the initial diagnosis, confine port sites to the abdominal midline because port site recurrence has been described, requiring extensive abdominal wall resection.

• Benign cystic mesothelioma tends to recur even with aggressive surgical removal; however, among recorded cases, no deaths have been attributable to this process.

• A combination of aggressive surgical debulking and systemic chemotherapy with cyclophosphamide, doxorubicin, and vincristine interspersed with ifosfamide, etoposide, and mesna (P6 protocol) appears to lead to an improved outcome in patients with desmoplastic small cell tumors.

• Treatment of peritoneal and GI hemangiomas has involved surgical removal.

The goals of pharmacotherapy are to induce remission, to prevent complications, and to reduce morbidity.

Drug Category: *Chemotherapeutic agents* -- Inhibit cell growth and proliferation. Agents used include cisplatin, doxorubicin, cyclophosphamide, carbo latin, and paclitaxel.

Drug Name	Cisplatin (Platinol) -- Inhibits DNA synthesis and thus cell proliferation by causing DNA cross-links and denaturation of double helix.
Adult Dose	75-100 mg/m2 q3wk IV; 90-270 mg/m2 IP; retain 4 h before draining with systemic sodium thiosulphate
Pediatric Dose	30-100 mg/m^2 q2-3wk

Contraindications	Documented hypersensitivity; preexisting renal insufficiency, myelosuppression, and hearing impairment
Interactions	Increase toxicity of bleomycin and ethacrynic acid
Pregnancy	D - Unsafe in pregnancy
Precautions	Administer adequate hydration before and 24 h after dosing to reduce risk of nephrotoxicity; hyperuricemia, nausea and vomiting, myelosuppression, anemia, peripheral neuropathy, ototoxicity, nephrotoxicity, acute renal failure, bradycardia, arrhythmia, mild alopecia, SIADH, hypomagnesemia, hypocalcemia, hypokalemia, hypophosphatemia, mouth sores, elevated liver enzymes, phlebitis, optic neuritis, blurred vision, and papilledema may occur; symptoms of overdosage include severe myelosuppression, intractable nausea and vomiting, kidney and liver failure, deafness, ocular toxicity, and neuritis; use proper handling and disposal
Drug Name	Doxorubicin (Adriamycin, Rubex) – Inhibits topoisomerase II and produces free radicals, which may cause the destruction of DNA. Combination of these events can, in turn, inhibit the growth of neoplastic cells.
Adult Dose	60-75 mg/m2 as a single dose, repeat q21d; 20-30 mg/m2/d for 2-3 d, repeat in 4 wk; or 20 mg/m2 once wk
Pediatric Dose	35-75 mg/m2 as a single dose, repeat q21d; 20-30 mg/m2 once weekly; or 60-90 mg/m2 continuous infusion over 96 h q3-4wk
Contraindications	Documented hypersensitivity; severe heart failure; cardiomyopathy; impaired cardiac function; preexisting myelosuppression
Interactions	May decrease phenytoin and digoxin plasma levels; phenobarbital may decrease plasma levels; cyclosporine may induce coma or seizures; mercaptopurine increases toxicity; cyclophosphamide increases cardiac toxicity

Pregnancy	D - Unsafe in pregnancy
Precautions	Extravasation may result in severe local tissue necrosis; reduce dose in patients with impaired hepatic function; use proper handling and disposal; total dose not to exceed 550 mg/m2 or 400 mg/m2 in patients with previous or concomitant treatment (ie, with daunorubicin, cyclophosphamide, or irradiation of the cardiac region); alopecia, nausea and vomiting, mucositis, ulceration and necrosis of the colon, anorexia and diarrhea, stomatitis, esophagitis, red discoloration of urine, myelosuppression, and cardiac toxicity may occur Acute arrhythmia, heart block, pericarditismyocarditis, and chronic cardiac toxicity as congestive cardiac failure may occur; facial flushing, hyperpigmentation of nail beds, erythematous streaking along the vein if administered too rapidly, hyperuricemia, fever, chills, urticaria, conjunctivitis, allergic reaction, and anaphylaxis may occur; radiation recall noticed in patients who have had prior irradiation; symptoms of overdosage include myelosuppression, nausea, vomiting, and myocardial toxicity
Drug Name	Carboplatin (Paraplatin) -- Analog of cisplatin. Has same efficacy as cisplatin but with better toxicity profile. Dose is based on following formula: Total dose (mg) = (target AUC) X (GFR = 25), where AUC (area under plasma concentration-time curve) is expressed in mg/mL/min and GFR (glomerular filtration rate) is expressed in mL/min.
Adult Dose	360 mg/m^2 IV q3wk as monotherapy or 300 mg/m^2 q4wk as combination therapy
Pediatric Dose	300-600 mg/m^2 IV q4wk
Contraindications	Documented hypersensitivity; bone marrow suppression
Pregnancy	D - Unsafe in pregnancy
Precautions	Monitor bone marrow function; use proper handling and disposal; high doses have resulted in severe LFT abnormalities; increased risk of allergic reactions if previously exposed to platinum therapy; hypocalcemia, hypomagnesemia,

	hyponatremia, hypokalemia, nausea, vomiting, stomatitis, myelosuppression, asthenia, alopecia, diarrhea, anorexia, peripheral neuropathy, and ototoxicity may occur; symptoms of overdosage include bone marrow suppression and hepatic toxicity
Drug Name	Cyclophosphamide (Neosar, Cytoxan) – Chemically related to nitrogen mustards. As an alkylating agent, the mechanism of action of the active metabolites may involve crosslinking of DNA, which may interfere with growth of normal and neoplastic cells.
Adult Dose	50-100 mg/m^2/d PO continuous therapy or 400-1000 mg/m^2 PO in divided doses 4-5 d intermittent therapy
Pediatric Dose	Administer as in adults
Contraindications	Documented hypersensitivity; severely depressed bone marrow function
Interactions	Allopurinol may increase risk of bleeding or infection and enhance myelosuppressive effects; may potentiate cyclophosphamide-induced cardiotoxicity; may reduce digoxin serum levels and antimicrobial effects of quinolones; chloramphenicol may increase Interactions half-life while decreasing metabolite concentrations; may increase effect of anticoagulants; coadministration with high doses of phenobarbital may increase rate of metabolism and leukopenic activity; thiazide diuretics may prolong cyclophosphamide-induced leukopenia and neuromuscular blockade by inhibiting cholinesterase activity
Pregnancy	D - Unsafe in pregnancy
Precautions	Regularly examine hematologic profile (particularly neutrophils and platelets) to monitor for hematopoietic suppression; regularly examine urine for RBCs, which may precede hemorrhagic cystitis; use proper handling and disposal Adverse effects include alopecia, sterility, nausea and vomiting, diarrhea, stomatitis, mucositis, jaundice, headache, skin rash, facial flushing, myelosuppression, cardiac Precautions dysfunction,

	dizziness, darkening of skin/fingernails, hyperglycemia, hypokalemia, hyperuricemia, SIADH, acute hemorrhagic cystitis, hepatic toxicity, renal tubular necrosis, nasal congestion, interstitial pulmonary fibrosis, and secondary malignancy (alone or in combination with other antineoplastics) Both bladder carcinoma and acute leukemia are well documented; symptoms of overdosage include myelosuppression, alopecia, nausea, and vomiting
Drug Name	Paclitaxel (Taxol) -- Mechanisms of action are tubulin polymerization and microtubule stabilization.
Adult Dose	175 mg/m^2 IV over 3 h q3wk; alternatively, 135 mg/m^2 IV over 24 h q3wk
Pediatric Dose	Not established
Contraindications	Documented hypersensitivity to paclitaxel or polyoxyethylated castor oil; peripheral neuropathy; bone marrow suppression; liver failure; severe cardiac disease
Interactions	Coadministration with cisplatin may further increase myelosuppression
Pregnancy	D - Unsafe in pregnancy
Precautions	Premedicate with steroids, H1 blockers, and H2 blockers to decrease risk of hypersensitivity reactions; current evidence indicates that prolongation of infusion >6 h plus premedication may minimize this effect; adverse reactions include hypotension, abnormal ECG tracings, alopecia, nausea and vomiting, diarrhea, mucositis, bleeding anemia neutropenia, thrombocytopenia, abnormal LFT results, peripheral neuropathy, myalgia, bradycardia, and radiation pneumonitis in patients receiving concurrent radiotherapy

Further Inpatient Care:

• Follow up to evaluate patients for complications of the cancer, spread of the cancer, and possible complications of therapy.

• Screening is also essential to help rule out known associated cancers and cancer syndromes.

Prognosis:

• Patients with peritoneal mesothelioma generally have a better prognosis compared to those with pleural mesothelioma. Original reports suggest a median survival of less than 1 year from the time of diagnosis; however, multiple varied treatment approaches may prolong long-term survival.

• See Mortality/Morbidity.

Medical/Legal Pitfalls:

• Failure to diagnose and appropriately treat cancers and precancerous lesions

• Failure to monitor to detect cancer recurrence and complications

• Failure to detect adverse effects and complications of therapy

BIBLIOGRAPHY

• Abeloff MD, Armitage JO, Lichter AS" Niederhuber JE: Clinical Oncology. 2nd ed. Philadelphia, Pa: Churchill Livingstone; 2000. .
• Clement PB: Reactive tumor-like lesions of the peritoneum. Am J Clin Pathol1995 Jun; 103(6): 673-6[Medline].
• Devita VT, Hellman S, Rosenthal SA: Cancer: Principles and Practice of Oncology. 5th ed. Philadelphia, Pa: Lippincott Williams & Wilkins; 1999.
• Ibarguen E, Sharp Hl, Snyder Cl, et al: Hemangiomatosis of the colon and peritoneum: case report and management discussion. Clin Pediatr (Phila) 1988 Sep; 27(9): 425-30[Medline].
• Noltenius HW: Manual of Oncology. Vol 1. Baltimore, Md: Urban and Schwarzenberg; 1981.
• Shefren G, Collin J, Soriero 0: Gliomatosis peritonei with malignant transformation: a case report and review of the literature. Am J Obstet Gynecol 1991 Jun; 164(6 Pt 1): 1617-20; discussion 1620-1 [Medline].

ONCOLOGY Vol 12, No 6 (June 1998)

Extraovarian Primary Peritoneal Carcinoma

Gamal H. Eltabbakh, MD, *Associate Professor and Director, Division of Gynecologic Oncology, The University ofVermont, Burlington, Vermont*
M. Steven Piver, MD, Director, *Gilda Radner Familial Ovarian Cancer Registry, Department of Gynecologic Oncology, Roswell Park Cancer Institute, Buffalo, New York*

History
Origin
Incidence
Risk Factors
Clinical Picture
Staging
Pathology
Diagnostic Criteria
Management
Survial
Prognostic Factors
Conclusions
References

Reviewer's Comments:

Robert E. Scully, MD, Professor of Pathology, *Emeritus Department of Pathology, Massachusetts General Hospital, Boston, Massachusetts*
Noelle Gillette, MD, *Fellow, Gynecologic Oncology*
Phillip J. Disaia, MD, *The DorothyMarsh Chair in Reproductive Biology, Professor, Department of Obstetrics/Gynecology, University of California at Irvine, Orange, California*

Extraovarian primary peritoneal carcinoma (EOPPC), a relatively newly defined disease that develops only in women, accounts for approximately 10% of cases with a presumed diagnosis of ovarian cancer. Characterized by abdominal carcinomatosis, uninvolved or minimally involved ovaries, and no identifiable primary, EOPPC has been reported following bilateral oophorectomy performed for benign disease or prophylaxis. Most cases are of serous histology; however, nonserous tumors have been observed. Although EOPPC is similar to serous ovarian carcinoma with respect to clinical presentation, histologic appearance, and response to chemotherapy, molecular and epidemiologic studies have indicated that it may be a separate entity. This review explores the clinical presentation, management, prognosis, and survival of EOPPC.

Extraovarian primary peritoneal carcinoma (EOPPC) is an adenocarcinoma that develops from the peritoneum lining the pelvis and abdomen and is characterized by abdominal carcinomatosis, uninvolved or minimally involved ovaries, and no identifiable primary tumor. This relatively newly defined disease entity occurs exclusively in women and has been reported following bilateral oophorectomy performed for benign disease or prophylaxis.[1] It accounts for approximately 10% of cases with a presumed diagnosis of ovarian cancer.[2]

Although most cases of EOPPC are of serous histology, nonserous tumors have been reported. [3] Different investigators have referred to EOPPC as serous surface papillary carcinoma,[1,4,5] primary peritoneal carcinoma,[6] peritoneal mesothelioma,[7] multiple focal extraovarian serous carcinoma,[8] primary peritoneal papillary serous adenocarcinoma,[3] serous surface carcinoma of the peritoneum,[9] extraovarian peritoneal serous papillary carcinoma,[10,11] extraovarian mUllerian adenocarcinoma,[12] normal-sized ovary carcinoma syndrome,[13] papillary serous carcinoma of the peritoneum,[14-16] and peritoneal papillary carcinoma.[17]

Extraovarian primary peritoneal carcinoma is similar in clinical presentation, histologic appearance, and response to serous ovarian carcinoma. However, molecular and epidemiologic studies[18,19] suggest that EOPPC may be a separate entity. This review examines the current literature on EOPPC, with an emphasis on its clinical presentation, management, prognosis, and survival.

History

The first case of EOPPC was reported by Swerdlow in 1959.[7] He described a 27-year-old woman experiencing pelvic pain, who, upon examination, was found to have an adnexal mass. Exploratory laparotomy revealed a friable pelvic tumor and normal fallopian tubes and ovaries. On microscopic examination, the tumor exhibited a papillary architecture and was most remarkable for large deposits of psammoma bodies.

Two years later, Rosenbloom and Foster[20] reported a case of pelvic peritoneal tumor, which they referred to as diffuse papillary mesothelioma. In 1974, Parmley and Woodruff[21] demonstrated that pelvic peritoneum had the potential to differentiate into a mullerian type of epithelium, and in 1977, Kannerstein et al[22] and Kannerstein and Churg[23] pointed out the importance of distinguishing EOPPC from peritoneal malignant mesothelioma, a condition that predominantly affects men and is associated with exposure to asbestos.

Origin

Two theories have been proposed to explain the development of EOPPC. Some authors[22] believe that embryonic germ cell rests remain along the gonadal embryonic pathway and that EOPPC develops from a malignant transformation of these cells. Other authors[21] contend that field carcinogenesis occurs, with the celomic epithelium lining the abdominal cavity (peritoneum) and the ovaries (germinal epithelium) manifesting a common response to an oncogenic stimulus.

Muto et al[18] demonstrated that four of six cases of EOPPC had different patterns of allelic loss at various anatomic sites, and one of these cases also had a p53 mutation present in some, but not all, anatomic sites. These findings are consistent with a multifocal origin for primary peritoneal carcinoma.

The same authors[24] had previously shown that, in advanced-stage epithelial ovarian cancer, the pattern of allelic loss, X chromosome inactivation, and p53 mutation was consistent with a unifocal origin. Contrary to Muto et al,[18] Kupryjanczyk et al,[25] using p53 mutation analysis, identified identical mutations in tumors obtained from different sites in two patients with primary peritoneal carcinoma. Again, these findings are consistent with a unifocal origin.

Role of BRCAl Mutations?

Mutations of the tumor-suppressor gene BRCAl have been implicated in the development of familial ovarian and breast cancer.[26,27] The role of BRCAl gene mutations in the development of EOPPC is uncertain. In the only molecular study reported to date, BRCAl germ-line mutations were identified in 3 (17.6%) of 17 EOPPC patients.[28] If these findings are confirmed by further studies, EOPPC should be considered a malignancy expressed in the familial breast-ovarian cancer syndrome.

Incidence

To date, ~500 cases of EOPPC have been reported in the literature. The relatively small number of reported cases is due to the facts that (1) EOPPC is a relatively newly defined disease entity and (2) most EOPPC cases are misdiagnosed as epithelial ovarian cancer.

Some authors [10] believe that the incidence of EOPPC is increasing. Centers that document the relative frequency of EOPPC and epithelial ovarian cancer report a ratio of approximately 1:10.[17,19,29] An autopsy study by Rothacker et al[2] demonstrated that EOPPC accounts for 8% of all autopsies with the final diagnosis of serous ovarian cancer. These authors[2] estimated an incidence of 1 case per 150,000 women per year in their geographic area.

Risk Factors

The risk factors for EOPPC are unknown. Unlike peritoneal mesothelioma, EOPPC has no association with exposure to asbestos.[2]

An epidemiologic study[19] that compared EOPPC patients with patients with epithelial ovarian cancer discovered some similarities and differences between the two groups. Compared with women with epithelial ovarian cancer, those with EOPPC were significantly older, had later menarche, and were less likely to have used perineal talc powder. On the other hand, there were no significant differences between the two groups with regard to race; education; income; marital status; smoking; history of the use of birth control pills or hormone replacement; history of tubal ligation or infertility; family history of ovarian, colorectal, or endometrial cancers; and personal history of breast or uterine cancers.

Clinical Picture

The clinical presentation of EOPPC is indistinguishable from that of advanced-stage epithelial ovarian cancer.[9-11,14-17] Most reported cases of EOPPC have been in white women, with a median age of 57 to 66 years.

The most common presenting symptoms include abdominal distention, pain, and gastrointestinal symptoms (nausea, vomiting, dyspepsia, or change in bowel habits). The most common presenting finding on physical examination is ascites, reported in approximately 85% of cases.

On exploratory laparotomy, a widespread intraperitoneal malignancy has been found, which usually involves the omentum and upper abdomen with minimal or no ovarian involvement. The operative findings of EOPPC are similar to those of advanced-stage epithelial ovarian cancer or peritoneal carcinomatosis from metastatic gastrointestinal cancers, except that the ovaries show minimal or no involvement and no primary can be found in the gastrointestinal tract or other organs. Because the ovaries look normal, EOPPC has sometimes been referred to as normal-sized ovary carcinoma syndrome. [13]

Approximately 3.2% to 21.2% of EOPPC patients have a history ofbilateral oophorectomy for benign disease or prophylaxis.[10,14,30] Extraovarian primary peritoneal carcinoma spreads mainly transperitoneally; however, lymphatic and blood-borne metastases have been suggested.[10,14,31] Metastasis to different groups of lymph nodes,[10,14] the liver parenchyma,[14] and the brain[31] have been reported.

Levels of the tumor marker CA 125 were elevated (> 35 U/mL) in most of the EOPPC patients in whom preoperative CA 125 values were known.[3,15,32] Some authors[3] have found that CA 125 levels correlate with the clinical status of the disease and response to therapy. In a group of 29 EOPPC patients, mean CA 125 values were similar to those of a group of27 women with epithelial ovarian cancer matched for age, stage, and grade. [15]

Staging

There is no separate staging system for EOPPC. Most investigators have used the International Federation of Obstetrics and Gynecology (FIGO) staging system for ovarian cancer [33] in EOPPC patients. Most cases reported in the literature have been stage III or IV. [3,10,17,30,32]

Pathology

The histology of EOPPC is indistinguishable from that of papillary serous ovarian carcinoma but is distinct from that of papillary mesothelioma.[9,34,35] Figures 1 and 2. show two examples of EOPPC. The tumor is characterized by a predominantly papillary pattern. The papillae are irregular in size and shape and usually contain psammoma bodies, which are abundant in some cases. The number of mitoses is usually> 20 per 10 high-power fields, and most cases are grade 2 or 3.[10,14] Ultrastructurally, EOPPC shows epithelial differentiation,

including cytoplasmic mucin, short and straight microvilli, cell junctions, and occasional cilia.[9]

The microscopic, histochemical, immunohistochemical, and ultrastructural features of EOPPC are similar to those of serous ovarian carcinoma.[9,34,35] Occasionally, it is difficult to differentiate this disease from papillary peritoneal mesothelioma on microscopic examination alone. In such cases, the panel of special stains listed in Table 1 may be helpful.

August et al [8] compared the gross, light microscopic, and ultrastructural features of EOPPC with those of serous ovarian carcinoma and malignant mesothelioma. They concluded that EOPPC probably arises from mesothelial cells modified by various mullerian influences and should be classified separately from the other two entities.

Most cases of EOPPC reported in the literature have been of serous histology. [3,10,14] However, other histologic variants of the mullerian system have been reported; specifically, endometrioid,[36] clear cell, [3,37] mucinous,[38] Brenner tumor,[39] and mixed mullerian tumors. [40] Clinical experience with nonserous primary peritoneal carcinomas is limited. However, nonserous and serous tumors appear to be similar with regard to prognosis and response to therapy. [3]

Molecular Changes

A few studies[6,12,18] have reported molecular changes associated with EOPPC. Using immunohistochemical techniques, Moll et al[6] found p53 overexpression in 83% of 29 EOPPC patients. These authors speculated that p53 inactivation is a critical early step in the development of this tumor, but not necessarily the first step. They also identified two cases of discordance for p53 immunopositivity among eight immunopositive tumors sampled that had at least two distinct anatomic sites. According to Moll et aI, these two cases support the concept of a multifocal origin of EOPPC.

Kowalski et al[12] investigated overexpression of the tumor-suppressor gene p53, the oncogene *HER-2/neu*, and DNA content measured by flow cytometry in 44 EOPPC patients and a matched control group of 44 epithelial ovarian cancer patients. The rate of p53 overexpression and the incidence of aneuploidy were similar in the two groups (48% vs 59% and 65% vs 63%, respectively). However, EOPPC tumors demonstrated almost twice the rate of*HER-2/neu* overexpression as did epithelial ovarian cancers (59% vs 36%; $P = .05$). These authors suggested that the genetic events responsible for malignant transformation in EOPPC may be distinct from those responsible for epithelial ovarian cancer.

Diagnostic Criteria

To achieve uniform reporting and improve understanding of the results of therapy in EOPPC patients, the Gynecologic Oncology Group has described the following diagnostic criteria[11]:

- Both ovaries must be physiologically normal in size (< 4.0 cm in largest diameter) or enlarged by a benign process.
- Tumor involvement at the extraovarian sites must be greater than that on the surface of either ovary.

• Microscopically, the ovarian component must be: (1) nonexistent, (2) confined to ovarian surface epithelium with no evidence of cortical invasion; (3) involve ovarian surface epithelium and underlying cortical stroma but with any given tumor size less than 5 ' 5 mm; and (4) tumor less than 5 ' 5 mm within ovarian stroma with or without associated surface disease.
• Histologic and cytologic characteristics of the tumor must be predominantly of the serous type that is similar or identical to any grade of ovarian serous papillary adenocarcinoma.

Management

The management of patients with EOPPC is similar to that of patients with epithelial ovarian cancer, and consists of cytoreductive surgery followed by multiagent cisp1atin (Platinol)-based chemotherapy.

Surgery

Many authors[3,11,14,15] have reported more limited success with primary cytoreductive surgery in patients with EOPPC than in those with epithelial ovarian cancer. The widespread nature of EOPPC, specifically in the upper abdomen, may account for this limited success. Optimal cytoreductive surgery (largest residual tumor mass < 2.0 cm) has been reported in 33% to 69% of EOPPC patients.[3,10,11,14-17]

Chemotherapy

Most [11,14,16,17], but not all, authors have found that patients with EOPPC have a similar response to chemotherapeutic agents as those with epithelial ovarian cancer. Cisplatin-based regimens have been the most common first-line chemotherapeutic regimens used in patients who have EOPPC. [3,10,11,1417,30]

Table 2 summarizes the literature on the different chemotherapeutic regimens described to date. Dalrymple et al[10] reported a relatively low overall response rate of 33.3% to the combination of chlorambucil (Leukeran) and cisplatin (N = 25) or chlorambucil alone (N = 5). Fromm et al [14] cited an overall response rate of 63.6% to different regimens of chemotherapy, half of which included cisplatin, alone or in combination with other drugs. Of 33 patients who underwent second-look laparotomy, 27.3% demonstrated a complete surgical response and 21.2%, a partial surgical response.

These authors [14] demonstrated that patients who receive cisplatin-based regimens have a significantly longer survival than patients who do not, and that patients given combination chemotherapy survive longer than those treated with single-agent regimens. On the other hand, White et al [29] reported median survival times of 15 and 16 months for single- and multiple-agent regimens, respectively, in a small group of 11 EOPPC patients.

Researchers at the Roswell Park Cancer Institute[17] reported an overall response rate of 65% in a group of 23 EOPPC patients treated primarily with cisplatin-based regimens following cytoreductive surgery. This response rate was comparable to that achieved by the authors with similar combinations in patients with ovarian carcinomas. Tumor grade did not

influence response to chemotherapy. These authors [17] suggested that EOPPC patients should be treated in a similar fashion as those with ovarian adenocarcinoma.

Ransom et al [16] made similar recommendations based on the treatment results of33 EOPPC patients. In a study of five EOPPC patients treated with cisplatin, doxorubicin, and cyclophosphamide (Cytoxan, Neosar) and two patients treated with cisplatin and cyclophosphamide, Altras et al [3] recorded complete responses in four patients and partial responses in three.

In a case-control study of 33 EOPPC patients and 33 patients with papillary serous ovarian carcinoma, Bloss et al [11] found no significant differences between the cases and controls with regard to tumor response to therapy, disease-free interval, and actuarial survival. In this study, 29 patients received the combination ofcisplatin, doxorubicin, and cyclophosphamide and 4 patients received cisplatin plus cyclophosphamide. Complete surgical responses occurred in 6 (18.0%) patients and partial responses in 15 (45%).

In contrast, in another case-control study comparing EOPPC and papillary serous ovarian carcinoma, Killackey and Davis[15] asserted that EOPPC patients have a poorer response to treatment with cisplatin-based regimens. However, these authors did not give details about response rates in the two treatment groups.

Paclitaxel-Cisplatin Combinations-In the first published report on the combination of paclitaxel (135mg/m2) and cisplatin (50 to 75 mg/m2), given for six cycles in four EOPPC patients, Menzin et al [41] described a complete surgical response in one patient and partial surgical responses in three patients.

Piver et al [30] reported the results of two sequential studies in which 46 patients with EOPPC received induction therapy with weekly cisplatin followed by either Platinol-Adriamycin-Cyclophosphamide (pAC; N = 25) or Taxol-Platinol (TP; N = 21). Surgical assessment of response was performed in 15 (60.0%) patients in the PAC trial and 13 (61.9%) in the TP trial. These authors found no statistically significant differences in overall response, surgical response, and complete surgical response rates between the PAC- and TP-treated patients (62.5% vs 70.0%, 73.3% vs 76.9%, and 13.3% vs 23.1 %, respectively). Rates of nausea and vomiting and peripheral neuropathy were significantly higher among patients who received TP.

Second-Line/Salvage Chemotherapy--Experience with second-line or salvage chemotherapy in EOPPC patients who demonstrate tumor recurrence or progression is limited. Bloss et al [11] utilized such agents as cisplatin, carboplatin (Paraplatin), doxorubicin, methotrexate, paclitaxel, and fluorouracil (5-FU) in 14 patients with recurrent or persistent EOPPC. Salvage chemotherapy was unsuccessful in achieving a durable complete response in these patients.

Dalrymple et al[10] reported partial responses to second-line therapy in three patients, two of whom received cisplatin alone and one ofwhom, cisplatin and etoposide.

Survival

Earlier studies[4,32,4l] of EOPPC described poor survival in the majority of patients. The 10 patients described by Mills et al[32] died within 52 months of diagnosis, and the longest survivor reported by Foyle et al [42] died 1.5 years after her initial symptoms.

Chen and Flam[43] were the first to report long-term survival. They described three patients who survived without evidence of disease for more than 5 years after treatment with surgery followed by the combination of cisplatin and doxorubicin with or without cyclophosphamide. In general, more recent studies on EOPPC have described better overall survival than earlier ones.

Reported median survival durations and 5-year survival rates among EOPPC patients are shown in Table 3. Median survival times vary between 7.0 and 27.8 months, while 5-year survival rates range from 0% to 26.5%.

Table 4 compares the survival of EOPPC patients with that of epithelial ovarian cancer patients. Gooneratne et al[4] reported a poorer survival in EOPPC patients than patients with epithelial ovarian cancer, but did not give full details. Dalrymple et al [10] cited a median survival of 11.3 months for patients with EOPPC, which is similar to the 13.5-month median survival for patients with ovarian carcinoma. None of their patients survived for 5 years.

Fromm et al [14] reported an overall median survival of24.0 months. In their study, median survival for patients treated with melphalan (Alkeran) was 8.6 months, as compared with 34.5 months for those given cisplatin and cyclophosphamide (P = .008). Overall, the 5-year survival rate for their patients was approximately 22% .

Bloss et al [11] described a median survival of20.0 months for EOPPC patients and 27.8 months for patients with papillary serous ovarian carcinoma matched for the extent of tumor before and following cytoreductive surgery, tumor grade, patient age, and treatment. The 5-year survival rate was approximately 15%.

In a study by Ransom et al,[16] median survival in a group of 33 EOPPC patients was 17 months. The 5-year survival rate reported by these authors was approximately 20%.

Killackey and Davis [15] reported a 10% survival rate at 5 years for EOPPC patients, as compared with a 37% rate for a matched group with papillary serous ovarian cancer. They found that mean disease-free survival was significantly shorter in EOPPC patients than in those with ovarian cancer (3.4 vs 11.7 months; P = .005).

Eltabbakh et al [44] described a median survival of 23.5 months for a group of 75 EOPPC patients and a 26.5% 5-year survival rate. In a study by Mulhollan et al, [5] the 2-year survival rate for a group of 33 patients with EOPPC was 39%. The 4-year survival rate for these patients was significantly longer than that for patients with serous carcinoma of the ovary (28% vs 9%; P = .03). Kowalski et al [12] reported a median survival of27.8 months and a 5-year survival rate of ~15%. Patients with serous psammocarcinoma, a specific type of EOPPC characterized by massive psammoma body formation and low-grade cytologic features, have excellent survival following surgery alone. [45]

Prognostic Factors

Knowledge about prognostic factors in EOPPC patients is limited. Fromm et al [14] demonstrated that patients whose tumors exhibited no mitosis survived significantly longer than those whose tumors showed mitosis. Survival also was longer in those who received multiple-agent chemotherapy, as compared with those treated with single-agent chemotherapy, and in those who received cisplatin-based regimens, as compared with those given non-cisplatin-containing regimens. On the other hand, these authors did not find age or residual tumor mass following primary cytoreductive surgery to be of prognostic significance.

Mulhollan et al [5] demonstrated that size of ovarian involvement and depth of ovarian stromal invasion by tumor was not predictive of survival. In the study by Ransom et al, [16] the only three long-term survivors had optimal cytoreductive surgery followed by cisplatin-based multiagent chemotherapy.

Piver et al [30] demonstrated that patients who underwent optimal cytoreductive surgery (largest residual tumor < 1 cm) had a significantly higher response rate to chemotherapy and longer survival than patients in whom optimal cytoreductive surgery was not achievable. In 46 patients who received cis-platin-based multiagent chemotherapy, median survival was 29.4 months in patients who underwent optimal cytoreductive surgery vs 18.6 months in those who had suboptimal surgery ($P = .008$).

These findings were confirmed by a larger study [44] involving 75 EOPPC patients treated in the same institution. Eltabbakh et al [44] demonstrated that patient age, stage, performance status, and size of residual tumor following primary cytoreductive surgery were significant prognostic factors on univariate analysis. On multivariate analysis, only performance status and residual tumor were independent prognostic factors. Tumor grade, histology, depth of ovarian involvement, preoperative CA 125 values, p53 overexpression, and estrogen- and progesterone-receptor status did not affect survival significantly. [44] However, ability to achieve optimal cytoreduction may be related to preoperative tumor volume and tumor biology. Patients with smaller preoperative tumor volume and those with biologically less aggressive tumors are more likely to have optimal cytoreduction.

In a study that involved three molecular markers, Kowalski et al[12] demonstrated that p53 and *HER-2/neu* overexpression and DNA content evaluated by flow cytometry had no prognostic significance.

Conclusions

Recognition of EOPPC seems to be increasing. Patients with EOPPC should be reported separately from those with ovarian carcinoma but should be treated in a similar fashion.

Recent reports [30,44] of the prognostic significance of residual tumor mandate that surgeons should make every effort to achieve maximal tumor debulking when faced with the occasional patient who has abdominal carcinomatosis, normal-sized ovaries, and no identifiable primary tumor.

References

1. Tobacman JK, Tucker MA, Kase R: Intraabdominal carcinomatosis after prophylactic oophorectomy in ovarian cancer prone families. Lancet 2:795-797, 1982.

2. Rothacker D, Mobius G: Varieties of serous surface papillary carcinoma of the peritoneum in Northern Germany: A thirty-year autopsy study. Int J Gynecol Patho114:31 0-318, 1995.

3. A1tras MM, Aviram R, Cohen I, et al: Primary peritoneal papillary serous adenocarcinoma: Clinical and management aspects. Gynecol OncoI40:230-236, 1991.

4. Gooneratne S, Sassone M, Blaustein A, et al: Serous surface papillary carcinoma of the ovary: A clinicopathologic study of 16 cases. Int J Gynecol Pathol 1:241-249, 1981.

5. Mulhollan TJ, Silva EG, Tornos C, et al: Ovarian involvement by serous surface papillary carcinoma. Int J Gynecol Pathol13:120-126, 1994.

6. Moll UM, Valea F, Chumas J: Role ofp53 alteration in primary peritoneal carcinoma. Int J Gynecol PathoI16:156-162,1997.

7. Swerdlow M: Mesothelioma of the pelvic peritoneum resembling papillary cystadenocarcinoma of the ovary: Case "report. Am J Obstet Gynecol 77:200, 1959.

8. August CZ, Murad TM, Newton M: Multiple focal extraovarian serous carcinoma. Int J Gynecol Pathol 4:11-23, 1985.
9. Truong LD, Maccato ML, Awalt H, et al: Serous surface carcinoma of the peritoneum: A clinicopathologic study of 22 cases. Hum Pathol 21 :99-110, 1990.

10. Dalrymple JC, Bannatyne P, Russell P, et al: Extraovarian peritoneal serous papillary carcinoma: A clinicopathologic study of31 cases. Cancer 64:110-115, 1989.

11. Bloss JD, Liao SY, Buller RE, et al: Extraovarian peritoneal serous papillary carcinoma: A case-control retrospective comparison to papillary adenocarcinoma of the ovary. Gynecol OncoI50:347-351, 1993.

12. Kowalski LD, Kanbour AI, Price FV, et al: A case-matched comparison of extraovarian vs primary ovarian adenocarcinoma. Cancer 79:1587-1594, 1997.

13. Feuer,GA, Shevchuk M, Calanog A: Normal-sized ovary carcinoma syndrome. Obstet Gynecol 73:786-792, 1989.

14. Fromm GL, Gershenson DM, Silva EG: Papillary serous carcinoma of the peritoneum. Obstet Gynecol 75:75-89, 1990.

15. Killackey MA, Davis AR: Papillary serous carcinoma of the peritoneal surface: Matched-case comparison with papillary serous ovarian carcinoma. Gynecol Oncol 51: 171-174, 1993.

16. Ransom DT, Shreyaskmar RP, Keeney GL, et al: Papillary serous adenocarcinoma of the peritoneum. Cancer 66:1091-1094, 1990.

17. Lele SB, Piver MS, Matharu J, et al: Peritoneal papillary carcinoma. Gynecol Oncol 31:315-320, 1988.

18. Muto MG, Welch WR, Mok SCR, et al: Evidence for a multifocal origin of papillary serous carcinoma of the peritoneum. Cancer Res 55:490-492, 1995.

19. Eltabbakh GR, Piver MS, Natarajan N, et al: Epidemiological differences between women with extra-ovarian primary peritoneal carcinoma and women with epithelial ovarian cancer. Obstet Gynecol 91 :254-259, 1998.

20. Rosenbloom MA, Foster RB: Probable pelvic mesothelioma: Report of a case and review of literature. Obstet GynecoI18:213-222, 1961.

21. Parmley TR, Woodruff JD: The ovarian mesothelioma. Am J Obstet GynecoI120:234-241, 1974.

22. Kannerstein M, Churg J, McCaughey WTE, et al: Papillary tumors of the peritoneum in women: Mesothelioma or papillary carcinoma. Am J Obstet GynecoI127:306-314, 1977.

23. Kannerstein M, Churg J: Peritoneal mesothelioma. Rum Pathol 8:83-84, 1977.

24. Tsao SW, Mok SCR, Knapp RC, et al: Molecular genetic evidence of a unifocal origin for human serous ovarian carcinomas. Gynecol OncoI48:5-10, 1993.

25. Kupryjanczyk J, Thor AD, Beauchamp R, et al: Ovarian, peritoneal, and endometrial serous carcinoma: Clonal origin of multifocal disease. Mod PathoI9:166-173, 1996.

26. Miki Y, Swensen J, Shattuck-Eidens D, et al: A strong candidate for the breast and ovarian cancer susceptibility gene BRCA1. Science 266:66-71, 1994.

27. Shattuck-Eidens D, McClure M, Simrad J, et al: A collaborative survey of80 mutations in the BRCAI breast and ovarian cancer susceptibility gene. JAMA 273:535-541, 1995.

28. Bandera CA, Muto MG, Berkowitz RS, et al: Germline BRCAI mutations in women with papillary serous carcinoma of the peritoneum (abstract). Gynecol OncoI64:297, 1997.

29. White PF, Merino MJ, Barwick KW: Serous surface papillary carcinoma of the ovary: A clinical, pathological, ultrastructural and immunohistochemical study of 11 cases. Pathol Annu 20:403-418, 1995.

30. Piver MS, Eltabbakh GR. Rempling RE, et al: Two sequential studies for primary peritoneal carcinoma: Induction with weekly cisplatin followed by either cisplatin-doxorubicin-cyclophosphamide or paclitaxel-cisplatin. Gynecol OncoI67:141-147, 1997.

31. Eltabbakh GR, Piver MS, Werness BA: Primary peritoneal adenocarcinoma metastatic to the brain. Gynecol OncoI66:160-163, 1997.

32. Mills SE, Andersen WA, Fechner RE, et al: Serous surface papillary carcinoma: A clinicopathologic study of 10 cases and comparison with stage III-IV ovarian serous carcinoma. Am J Surg PathoI12:827834, 1988.

33. Cancer Committee of the International Federation of Gynecology and Obstetrics: Staging Announcement, FIGO Cancer Committee. Gynecol OncoI25:383-385, 1986.

34. Resta L, Maiorano E, Zito FA, et al: Multifocal extraovarian serous carcinoma: A histochemical and immunohistochemical study. Eur J Gynecol OncoI9:474-478, 1988.

35. Raju D, Fine G, Greenwald KA, et al: Primary papillary serous neoplasia of the peritoneum: A clinico-pathologic and ultrastructural study of eight cases. Hum Pathol 20:426-436, 1989.

36. Clark JE, Wood H, Jaffurs WJ, Fabro S: Endometrioid-type cystadenocarcinoma arising in the mesosalpinx. Obstet GynecoI54:656-658, 1979.

37. Lee KR, Verma D, Belinson JL: Primary clear cell carcinoma of the peritoneum. Gynecol Oncol 41 :259-262, 1991.

38. Banerjee R, Gough F: Cystic mucinous tumors of the mesentery and retroperitoneum: Report of three cases. Histopathology 12:527-532, 1988.

39. Hampton HL, Hufman HT, Meeks GR: Extraovarian Brenner tumors. Obstet Gynecol 79:844-846, 1992.

40. Mire JL, Fenoglio-Preiser CM, Husseinzadeh N: Malignant mixed mullerian tumor of extraovarian secondary mullerian system: Report of two cases and review of the literature. Arch Pathol Lab Med 119:1044-1049, 1995.

41. Menzin AW, Aikins JK, Wheeler JE, et al: Surgically documented responses to paclitaxel and cisplatin in patients with primary peritoneal carcinoma. Gynecol OncoI62:55-58, 1996.

42. Foyle A, Al Jabi M, McCaughey WTE: Papillary peritoneal tumors in women. Am J Surg Pathol 5:241-249, 1981.

43. Chen KTK, Flam MS: Peritoneal papillary serous carcinoma with long-term survival. Cancer 58:1371-1373, 1986.

44. Eltabbakh GH, Wemess BA, Piver MS, et al: Prognostic factors in extra-ovarian primary peritoneal carcinoma (abstract). Gynecol OncoI68:112, 1998.

45. Gilks CB, Bell DA, Scully RE: Serous psammocarcinoma of the ovary and peritoneum. Int J Gynecol PathoI9:110-121, 1990.

The Eltabbakh/Piver Article Reviewed

Robert E. Scully, MD, Professor of Pathology, *Emeritus Department of Pathology, Massachusetts General Hospital, Boston, Massachusetts*

The distribution of abdominal serous carcinoma in the female ranges from ovarian carcinoma with no tumor involvement of the peritoneum to peritoneal carcinoma with no evidence of carcinoma in the ovary. For the purposes of investigation and patient care, it has been necessary to formulate criteria to distinguish tumors that are most probably primary ovarian carcinomas from those that are most likely primary peritoneal cancers.

The presently accepted criteria for making this distinction are based on minimal scientific evidence. It is well-known that in organs other than the ovary (for example, the breast, thyroid gland, lung, and stomach), tiny primary tumors may be associated with large metastases or extensive tumor spread. Therefore, it is likely that some tumors designated as primary peritoneal carcinoma according to current criteria are actually small ovarian cancers that find the peritoneum a more hospitable site for growth than the ovary. Possible reasons why the peritoneum may provide a more favorable environment for carcinoma than the ovary include the greater density of ovarian tissue, which may inhibit invasion of tumor cells originating within its superficial layers; and the production of a tumor-inhibitory substance by the ovarian stroma (which has been demonstrated in vitro).[I]

We may never be able to distinguish, on scientific grounds, between primary ovarian and primary peritoneal serous carcinomas in every case. Clonality studies on a limited number of presumably primary peritoneal tumors have suggested a multifocal origin, in contrast to the usual finding of clonality in cases of typical ovarian carcinoma with peritoneal spread. More extensive studies of this type should be performed to confirm these results. At present, such studies cannot be performed routinely, however, and the criteria currently used to distinguish these two forms of serous neoplasia are the only ones available in the great majority of cases.

In addition to the Gynecologic Oncology Group (GOG) criteria cited by the authors, it is important to review the slides of a previously removed ovary, fallopian tube, or uterus in cases of suspected primary peritoneal serous carcinoma. This is particularly crucial since there have been cases in which tiny tumors were present in an ovary at a time when no peritoneal disease was recognized, and the patient returned subsequently with peritoneal involvement. In such cases, it may be difficult to determine without clonality studies whether the peritoneal tumor is a new primary tumor or a metastasis from the ovary.

Interesting Related Phenomena

The review by Eltabbakh and Piver provides a succinct summary of the clinicopathologic features of primary peritoneal serous carcinomas. It does not mention a number of related phenomena, which are of equal scientific interest. For example, one school of thought holds that what most investigators accept as peritoneal metastases of typical ovarian serous cancers may, in some cases, reflect an independent primary peritoneal cancer. Genetic studies to date, however, have not supported this speculation.

Also, not discussed in the review is the observation that primary peritoneal serous carcinomas are only part of the spectrum of primary peritoneal serous lesions. The benign counterpart is

endosalpingiosis, in which gland-like structures and/or papillae, lined by tubal-type epithelium, are found just beneath or on the peritoneal surface. This disorder is associated most often with chronic salpingitis and ovarian serous borderline tumors. The association with chronic salpingitis suggests that shedding of tubal epithelial cells onto the peritoneum is a route of development of endosalpingiosis.

Primary serous borderline tumors of the peritoneum have also been reported, albeit in fewer numbers than carcinomas.[2-4] These primary serous borderline tumors have an excellent prognosis, although rare cases have been reported in which transformation to carcinoma has been observed on follow-up examination.[2,4] It is interesting that 41% to 99% of primary serous borderline tumors of the peritoneum are accompanied by endosalpingiosis, suggesting an origin therein.[2-4]

Endosalpingiosis is also a legitimate candidate for a precursor to primary peritoneal serous carcinoma. In one series, 2 of 14 carcinomas of this type were associated with this disorder.[4] The much lower reported frequency of endosalpingiosis in the carcinoma cases may be attributable to a failure to record the lesion in the various reported series, most of which have limited pathologic data, or to biopsy of only obviously malignant lesions, which might have obliterated underlying endosalpingiosis. A careful search for endosalpingiosis in future cases may provide a clue as to whether it is a precursor to carcinoma.

Roswell Park Studies May Provide New Insights

The authors do not provide any details about papers currently in press from their institution that pertain to several aspects of primary peritoneal serous carcinomas. One cited conclusion is that the grade of the tumor is not a prognostic factor. However, a few reports of small series in the literature suggest that patients with grade 1 carcinomas have a better outcome than do those with higher-grade tumors. Indeed, the most highly differentiated form of serous carcinoma, the psammocarcinoma, which arises most often in the ovary but also on the peritoneum, appears to have such an excellent prognosis that some authors have concluded that chemotherapy is not indicated even in the presence of residual disease.[4,5]

If low-grade serous carcinoma of the peritoneum is shown to be associated with the same prognosis as high-grade disease in large series, the finding may not reflect the natural history of these two subtypes, but rather, the much better response to chemotherapy of the high-grade tumors. Details about the impact of grading on prognosis are eagerly awaited.

Another as yet unpublished study from Roswell Park Cancer Institute that should prove of interest is the epidemiologic investigation. The review by Eltabbakh and Piver does not mention the possible roles that parity and oral contraceptive intake may play in the development of primary peritoneal serous carcinoma. These prominent factors in the background of ovarian serous carcinoma have led to wide acceptance of the incessant ovulation theory. More detail on the authors' study may be illuminating in this respect.

References

1. Karlan BY, Baldwin RL, Cirisano ED, et al: Secreted ovarian stromal substance inhibits ovarian epithelial cell proliferation. Gynecol Oncol 59:67-74, 1995.

2. Bell DA, Scully RE: Serous borderline tumors of the peritoneum. Am J Surg Pathol14:230-249, 1990.

The Eltabbakh/Piver Article Reviewed

Noelle Gillette, MD, *Fellow, Gynecologic Oncology*
Phillip J. Disaia, MD, *The Dorothy Marsh Chair in Reproductive Biology, Professor, Department of Obstetrics/Gynecology, University of California at Irvine, Orange, California*

Drs. Eltabbakh and Piver present a comprehensive review of the management and prognosis of patients with extraovarian primary peritoneal carcinoma (EOPPC). Increased recognition and more precise definition have led many physicians and scientists to recognize EOPPC as a distinct clinical entity with a unique etiology. However, staging and treatment criteria for EOPPC have been modeled after criteria for papillary serous ovarian cancer, which is clinically and histologically similar. The Gynecologic Oncology Group (GOG) has allowed the inclusion of patients with EOPPC into clinical trials designed for patients with epithelial ovarian cancer.

Treatment Approach

It has been our practice at the University of California, Irvine, to treat patients with EOPPC and advanced epithelial ovarian cancer with the same approach; namely, maximal surgical debulking followed by platinum-based chemotherapy. In the case-control study by Bloss et al, patients with EOPPC were selected based on a standardized definition from the GOG and were compared to matched ovarian cancer controls. [1] In addition, all patients without clinical recurrence underwent second-look laparotomies so that the responses could be surgically documented. The patients with EOPPC and those with ovarian cancer had a similar response to primary chemotherapy, disease-free interval, salvage chemotherapy, and median survival. The numbers in this study were too small to examine the effectiveness of cytoreductive surgery, and disease was optimally debulked to less than 2 cm in only one-third of patients.

In the more recent study by Piver et al, patients with EOPPC were also included based on the GOG definition, and optimal debulking to less than 1 cm was achieved in 70%.[2] A statistically significant improvement in survival was noted in patients in whom optimal cytoreduction was accomplished.

Molecular Studies

Even though EOPPC is treated in the same manner as ovarian cancer, molecular studies suggest that it is a distinct disease entity. The clinical and histologic similarities may be explained by the fact that the peritoneal mesothelium and the mullerian duct epithelium have a common celomic origin. It is generally believed that cells within a tumor are derived from a single transformed cell. Genetic studies of ovarian cancer have supported this unifocal-origin theory by demonstrating identical p53 mutations and loss of heterozygosity at primary and metastatic sites.

The leading hypothesis of the etiology of EOPPC suggests that field carcinogenesis induces multifocal malignant transformation of the abdominal and pelvic peritoneum. The study by Muto et al supports the multifocal origin of EOPPC by demonstrating different p53 mutations and allelic loss at varied tumor sites in the same patient.[3]

The distinct nature of this disease is also supported by the occasional development of diffuse carcinomatosis that is histologically indistinguishable from epithelial ovarian cancer many years after prophylactic oophorectomy performed because of familial ovarian cancer. A review of the Gilda Radner Familial Ovarian Cancer Registry identified 324 women who had a prophylactic oophorectomy.[4] In this group ofpatients, six cases of EOPPC were diagnosed, indicating that prophylactic oophorectomy does not fully prevent familial ovarian cancer.

Summary

Extraovarian primary peritoneal carcinoma exemplifies the problems associated with the management of ovarian cancer. Since no identifiable precursor lesions exist, there is no adequate screening test, and the majority of patients present with widespread intraperitoneal tumor. Since drug resistance develops in most patients, the survival rate is poor.

It is clear that alternative treatments are needed. Perhaps future studies of EOPPC will elucidate the molecular events that lead to the development of these aggressive malignancies and, thus, improve treatment and outcome.

References

1. Bloss JD, Liao SY, Buller RE, et al: Extraovarian peritoneal serous papillary carcinoma: A case control retrospective comparison to papillary adenocarcinoma of the ovary. Gynecol Onco150:347351,1993.

2. Piver MS, Eltabbakh GH, Hempling RE, et al: Two sequential studies for primary peritoneal carcinoma: Induction with weekly cisplatinum followed by either cisplatinum-doxorubicincyclophosphamide or paclitaxel-cisplatin. Gynecol Onco167:141-146, 1997.

3. Muto MG, Welch WR, et al: Evidence for a multifocal origin of papillary serous carcinoma of the peritoneum. Cancer Res 55:490-492, 1995.

4. Piver MS, Jishi MF, et al: Primary peritoneal carcinoma after prophylactic oophorectomy in women with a family history of ovarian cancer. Cancer 71:2751-2755, 1993.

ELSEVIER

AMERICAN JOURNAL of OBSTETRICS and GYNECOLOGY

www.elsevier.com/locate/ajog

Comparison between primary peritoneal and epithelial ovarian carcinoma: A population-based study

Giulia Barda, MD,[a,b] Joseph Menczer, MD,[a,b],* Angela Chetrit, MSc,[c] F. Lubin, MSc,[c] Oani Beck, MD,[d] Benjamin Piura, MD,[e] Marek Glezerman, MD,[a,b] Baruch Modan, MD,[b,c,t] Siegal Sadetzki, MD, MPH[b,c] for the National Israel Ovarian Cancer Group

Gynecologic Oncology Unit, Department of Obstetrics and Gynecology, E. Wolfson Medical Center, Holon[a]; Tel Aviv University, Faculty of Medicine, Tel Aviv[b]; Cancer Epidemiology Unit, Gertner Institutefor Epidemiology and Health Policy, Sheba Medical Center, Tel Hashomer[c] ; Gynecologic Oncology Unit, Department of Obstetrics and Gynecology, Rambam Medical Center, Rappaport Faculty of Medicine, Technion, Israel Institute of Technology, Haifa[d] ; and Gynecologic Oncology Unit, Department of Obstetrics and Gynecology, Soroka Medical Center, Faculty of Health Sciences, Ben-Gurion University of the Negev, Negev, Israel[e]

Received for publication March 27, 2003; revised July 11, 2003; accepted September 29, 2003

KEY WORDS
Primary peritoneal carcinoma
Invasive epithelial ovarian carcinoma

Objective: This study was undertaken to characterize primary peritoneal carcinoma (PPC) compared with ovarian carcinoma (OvC).
Study design: Within the framework of a nationwide epidemiologic Israeli study, 95 PPC patients were identified and compared with 117 FIGO stage III-IV epithelial OvC patients matched by age and continent of birth. Data were abstracted from medical records and personal interviews.
Results: Our data confirm the similarities between PPC and Ove. A higher rate of abdominal distention, volume of ascites, and malignant cells in ascitic fluid and lower rate of pelvic palpable mass and personal breast cancer history were found in the PPC compared with the OvC group. The overall survival was similar in both groups (30-33 months). In optimally cytoreduced patients, survival was better in the OvC group. Diameter of residual disease was associated with better survival only in the OvC group.
Conclusion: The clinical differences do not enable a preoperative distinction between the neoplasms.
© 2004 Elsevier Inc. All rights reserved.

The current entity defined as primary peritoneal carcinoma (PPC) has previously been referred to by a variety of names.[1] Histologically, it is identical to invasive epithelial ovarian carcinoma (OvC); however, it involves only the peritoneal surfaces with minimal or no involvement of the ovaries. The predominant histologic type is serous but other types have also been reported. [1-3] This malignancy may also be diagnosed in women many years after oophorectomy has been performed for benign reasons4 or after prophylactic oophorectomy has been performed in women with a hereditary susceptibility to ovarian cancer.[5]

The precise incidence rates of PPC are not available, and data from individual institutions indicate a 1:10 ratio of PPC to OvC.[6-8] Most reported series are small, usually comprising about 15 to 45 cases.[4, 6-15] Only few studies comprise a somewhat larger number of patients. [2,7,16] According to these reports, the clinical presentation, diagnosis, treatment, and course of this malignancy are also similar to those of OvC. Nevertheless, epidemiologic, clinical, and biomolecular differences between the 2 neoplasms have been reported.[2,3]

The aim of this study was to characterize selected demographic data of PPC patients and compare clinicopathologic features of this group with those of a group of stage III-IV OvC patients.

Materials and methods

All incident cases of histologically confirmed cancer of the ovary or peritoneum (International Classification of Disease-9th [ICD-9] Revision 183 or158), diagnosed in Israeli Jewish women between March 1, 1994, and June 30, 1999, were identified within the framework of an ongoing nationwide epidemiologic study of these neoplasms. The study population was accrued through an active continuous identification of all patients whose disease was newly diagnosed in all the departments of gynecology in Israel. Pathology and oncology departments were checked monthly as well to ensure completeness of case identification. Personal interviews were conducted covering a wide range of topics, including demographic details and information on life-style habits, hormonal, reproductive, and family history and other potential risk factors. Age at diagnosis, type, and stage of tumor were abstracted from medical records. More details on the case-control study methodology were previously described.[17] The histologic diagnosis of OvC and PPC was based on the original pathology report reviewed and signed by 2 certified pathologists. During the study period, a total of 1226 patients had invasive epithelial OvC diagnosed. The criteria for diagnosis of PPC were according to those of the Gynecologic Oncology Group, namely:

1. Both ovaries are normal size, and their largest diameter does not exceed 5 cm;
2. The involvement in the extra ovarian sites must be greater than the involvement on the surface of either ovary; and
3. Microscopically, the ovarian component must be 1 of the following:
    a. nonexistent or
    b. confined to ovarian surface epithelium or superficially invading the underlying cortical stroma with any given tumor size less than 5X 5 mm.

In addition, we included 9 patients who previously underwent bilateral oophorectomy for benign or prophylactic reasons and excluded patients who received neoadjuvant chemotherapy. According to the previously described criteria, 95 PPCs were diagnosed.

The OvC comparison group included 117 FIGO stage III-IV OvC patients randomly matched by age (±2 years) and continent of birth to the PPC group. For the above mentioned PPC and OvC comparison groups, additional information, namely, symptoms at diagnosis, physical findings, diagnostic evaluation, amount of ascites at surgery, diameter of residual disease, postoperative complications, postoperative treatment and treatment response, were subsequently supplemented from files in the individual institutions. The vital status of the patients was updated to August 1, 2002, through the Israel Central Population Registry.

Statistical analysis

The X^2 test was used for comparison of categorical variables and one-way analysis of variance w was performed for continuous variables between the PPC and the OvC groups.

Survival curves were calculated with the KaplanMeier method and compared by the log-rank test. Median survival time is presented with the Brookmeyer 95% CI.

Results

The median age of PPC patients was 66 years (range 2583) and 61.1% were of Ashkenazi (European/American) origin (not shown).

Table I presents clinical characteristics of PPC and OvC patients. About half of the patients in both groups presented with abdominal pain, and approximately 32% and 25% of PPC and OvC patients, respectively, reported gastrointestinal symptoms. On physical examination, significantly more PPC patients than OvC patients had abdominal distention and presented with no palpable pelvic mass. Preoperative abdomino-pelvic computed tomographic scans and gastrointestinal studies, such as barium enema radiographs and endoscopies, were performed more often in PPC patients than in OvC patients. In both groups, the majority of those who had preoperative serum CA 125 assessment had elevated levels (> 35 U/mL). A small number of PPC and OvC patients (14 and 12, respectively) had also serum CA 19.9 levels evaluated; of these, more PPC patients than OvC patients had elevated CA 19.9 levels (92.9% vs 50.0%; *P* = .03) (not shown).

Among those patients who underwent preoperative paracentesis, the percentage of patients with malignant cells in the ascitic fluid was significantly higher in the PPC group.

Table I Clinical characteristics of pPC and OvCpatients

	PPC (n=95)		OvC (n = 117)		
Main presenting symptom*	No.	%	No.	%	*P*
Abdominal pain	51	53.6	60	51.3	NS
Gastrointestinal symptoms	30	31.6	29	24.8	NS
Abdominal distention	45	47.4	27	23.1	.001
Weight loss	14	14.7	22	18.8	NS
Other	16	16.8	30	25.6	NS
Pelvic mass palbable					.001
No	49	51.6	22	18.8	
Yes	25	26.3	65	55.6	
Not specified	21	22.1	30	25.6	

Diagnostic procedures [t]					
Pelvic ultrasonography	68	71.6	94	80.3	NS
CT scan	73	76.8	76	65.0	.06
Gastrointestinal studies	44	46.3	40	34.2	.07
Tumor markers					
CA					
125 performed	71	74.7	92	78.6	NS
> 35 U/mL	67	94.4	85	93.4	NS
Paracentesis performed	47	49.5	58	49.6	NS
Malignant cells present	42	87.5	39	67.2	.02

NS, Not significant.
[*] Patients had morethan 1 presentirig.symptom.
[t] Patients had morethan 1 diagnostic procedure.

Table II presents selected operative, postoperative, and pathologic data of the PPC and OvC patients. None of the patients in the PPC group and only 3 of the OvC group had stage IlIA. In stage IIIB, there were 1 and 6 patients in the PPC and OvC groups, respectively. Thus, stage III represents mainly stage IIIC patients in both groups (98.9% and 91.2% for PPC and OvC, respectively).

All the PPC patients who were assigned to stage IV had pleural effusion positive for malignant cells only. Of the 15 stage IV OvC patients, 4 had liver metastasis, 2 had extraperitoneal metastasis, and 9 had pleural effusion positive for malignant cells. Significantly more PPC than OvC patients had stage III disease at diagnosis and had a high volume (> 1 L) of ascites. A large proportion (42% and 46%) of patients in both groups underwent an extensive operative procedure (total abdominal hysterectomy, bilateral adnexectomy, and omentectomy). Similar rates of PPC and OvC patients had 2 cm or less residual tumor (45.3% and 37.6%, respectively) and operative complications. The most prevalent histologic type seen in both groups was serous carcinoma, being 80% in the PPC and 66% in the OvC group *(P* = .02).

As for the oncologic treatment, the majority of PPC and OvC patients (83.2% and 72.7%, respectively) were treated postoperatively by platin-based combination chemotherapy and the majority completed 6 or more treatment courses (75.8 and 70.1 %, respectively). A significantly higher proportion of PPC than OvC patients had paclitaxel + platin combination chemotherapy (63.2% vs 46.2%, respectively; *P* = .02). Of those patients who completed chemotherapy, an initial complete response was observed in 63.2% of PPC patients and 73.7% of ove patients (data not shown).

Table II Selected operative, .postoperative, and hystopathologic data of PPCand OvC patients

	PPC (n=95)		OvC (n = 117)		
Stage at diagnosis	No.	%	No.	%	P
III	92	96.8	102	87.2	.01
IV	3	3.2	1.5	12.8	
Volume of					

ascites (Li)					
None	3	3.2	12.	10.3	
≤ 1	8	8.4	17	14.5	
> 1	55	57.9	33	28.3	.008 *
Not estimated	10	10.5	22	18.8	
Presence of ascites unknown	19	20.0	33	28.2	
Tye of Surgery NS +					
Adnexectomy	2	2.1	7	6.0	
Omentectomy	14	14.7	5	4.3	
TAH + adnexectomy			5	4.3	
Adnexectomy + omentectomy	33	34.7	32	27.3	
TAH + adnexectomy + omentectomy	40	42.1	54	46.2	
Biopsy only	1	1.1	6	5.1	
Other	3	3.1			
Unknown	2	2.1	8	6.8	
Residual tumor diameter					NS
≤ 2 cm	43	45.3	44	37.6	
> 2 cm	33	34.7	44	37.6	
No residual tumor	1	1.1	5	4.3	
Not specified	18	19.0	24	20.5	
Operative complications	21	22.1	21	17.9	NS
Hemorrhage	3	3.2	4	0.9	
Infection	6	6.3	7	6.0	
Intestinal	4	4.2	6	5.1	NS
Wound dehiscence	6	6.3	2	1.7	
Other	2	2.1	2	1.7	
Histologic type					
Serous	76	80.0	77	65.8	.02±
Mucinous			1	.08	
Endometrioid			14	12.0	
Clear cell			23	19.9	
Grade					.04
G1	6	6.3	7	6.0	
G2,3	59	62.1	90	76.9	

Unknown	30	31.6	20	17.1	

TAH, Total abdominal hysterectomy.
[*] Comparison of none, ~ 1 to> 1 L.
[t] Comparison of TAH+adnexectomy+omentectomy to other operations.
[±] Serous vs others.

Table· III Selected possible risk factors> of PPC and OvC in interviewed patients

	PPC (n=80)		OvC{n=98)		
	No.	%	No.	%	*P*
Age at menarche					
<13	25	31.2	29	29.6	
≥ 13	53	66.3	66	67.3	
Unknown	2	2.5	3	3.1	
Oral conctraceptive use					NS
Ever users	8	10.0	12	12.2	
Never	72	90.0	86	87.8	
History of infertility					NS
Yes	3	3.8	4	4.1	
No	77	96.3	94	95.9	
Parity					NS
0	5	6.3	11	11.2	
1	6	7.5	12	12.3	
2-3	48	60.0	51	52.0	
4 +	21	26.3	24	24.5	
Menopausal status					NS
Pre	20	25.0	25	25.5	
Post	60	75.0	73	74.5	
Perineal talc					NS
Used	2	2.5	7	7.1	
Not used	77	96.2	89	90.8	
Unknown	1	1.3	2	2.1	
Clinical mumps history					NS
Yes	39	48.7	48	49.0	
No	20	25.0	20	20.4	
Unknown	21	26.3	30	30.6	
Family cancer history					NS
Ovarian	5	6.3	3	3.1	
Breast	8	10.0	12	12.2	
Ovarian + Breast	2	2.5			
Breast cancer history					.01
Yes	1	1.3	10	10.2	
No	78	97.4	86	87.8	
Unknown	1	1.3	3	3.1	

Of the 212 women (95 PPC and 117 OvC) included in the present analysis, 84% were interviewed, 8% did not consent to be interviewed, 6.5% were physically or mentally incapable of participating in the interview, and 1.5% died before the interview. Table **III** presents information with regard to possible risk factors obtained from the personal interview conducted for 80 (84.4%) of the PPC patients and 98 (83.8%) of the OvC patients.

The distribution of age at menarche, oral contraceptive use, history of infertility, number of births, menopausal status, use of perineal talc, previous history of clinical mumps, and a history of cancer in the family was similar in both patient groups. The median age of menopause onset was 50 years in PPC patients as well as in OvC patients. A significantly lower rate of previous personal breast cancer history was reported by the PPC group *(P* = .01).

The total median survival was similar in both groups, being 33 and 30 months in the PPC and OvC groups, respectively (Table IV). No difference between the groups was observed with regard to grade and volume of ascites. In patients with 2 cm or less residual tumor, a significantly better survival among OvC patients than among PPC patients was observed. We also evaluated, within each group of patients, the effect of volume of ascites and diameter of residual tumor on survival. In OvC patients a better survival was observed among those with 1 L or less of ascites but did not reach significance. The survival of OvC patients with 2 cm or less residual tumor was significantly better than in patients with greater than 2 cm residual tumor *(P* = .02). In PPC patients, no such effects on survival were observed.

Comment

The question of PPC as a separate disease entity is widely discussed. Several studies compared PPC patients with OvC patients.[2,6,7,10,12-14,16] In many respects such as presenting symptoms, level of CA 125, and operative and postoperative management, our series of PPC patients is similar to patients in previous studies.[6-8,10-12]
In our study, significantly more PPC patients than OvC patients had abdominal distention at presentation as was also found by others l4 and is in line with our finding that significantly more PPC patients than OvC patients had more than 1 L of ascites at operation.

The percentage of patients in the PPC group that underwent preoperative gastrointestinal studies was significantly higher than in the OvC group. This does not seem to be due to a difference in the rate of gastrointestinal symptoms but rather to a significantly higher rate of PPC patients with no palpable pelvic mass, therefore raising the concern of a nongynecologic malignancy. A similarly large proportion of patients in both groups underwent preoperative paracenthesis. However, the percentage of patients with malignant cells in the ascetic fluid was significantly higher in the PPC group. The reason for this finding is not clear, but it may signify that PPC has a higher tendency for malignant cell desquamation. In one study of 28 PPC patients,14 all had positive cytology. It is, however, not clear whether the ascetic fluid in that study has been

obtained preoperatively or intraoperatively. As reported by others[11,12,14] the serum CA 125 levels were elevated in most PPC patients. The proportion of patients with elevated CA 125 levels was similar in both groups of our patients. This concurs with other studies that reported no statistically different mean CA 125 levels in PPC and OvC patients. [12,14] Interestingly, among the small number of patients in our study who underwent assessment of serum of the CA 19.9 level, a significantly higher percentage of PPC patients had an elevated value. This finding should be verified in a larger group of patients because it may aid in the preoperative distinction between PPC and Ovc.

In addition, we found that PPC patients had a significantly lower rate of previous personal breast cancer history. This finding was unexpected in view of the similar rate of BRCAl, 2 mutations in the same groups of PPC and OvC patients previously reported by US. [18] The significantly lower rate of previous personal breast cancer history observed in the current study does not agree with findings in other smaller series. On the basis of the 14 PPC and 267 OvC patients who responded to a question regarding a personal history of breast, colorectal and uterine cancer, Eltabbakh et al found no difference between PPC and OvC patients. In an Israeli study, no significant difference was observed between 28 PPC and 35 OvC patients diagnosed in one institution, with regard to a history of an unspecified second primary cancer in the past. [14]

As in other studies,[6,8,1l,14] all our PPC patients had stage **III** or IV disease at diagnosis. However, significantly more PPC patients than OvC patients in our study were diagnosed with stage **III** disease. This finding also persisted when the stage distribution of PPC patients was compared with that of the total group of 1226 epithelial invasive OvC patients in a previous report by us. [17] The reason for this difference is not clear, but it may indicate that PPC tends to remain confined to the peritoneal cavity for a longer period than OvC or is diagnosed earlier.

The rate of optimal cytoreduction in PPC has been variously reported as 33% to 70%[6-8,10-12,14,19,20] and the rate in our study (45.3%) is within this range. Some authors reported that surgical optimal cytoreduction (diameter of largest residual tumor ~ 2 cm) is less successful in PPC patients [7,11,12,14,20] compared with OvC patients. We found no difference between PPC and OvC in the rate of optimal cytoreduction.

A similarly very high proportion of patients in both groups received postoperative platin-based chemotherapy and had an initial favorable response. This concurs with several other reports. [7,8,10,14] The reason for the significantly higher rate of PPC patients than OvC patients who received the combination of paclitaxel + platin, is obscure.

The most extensive comparison of PPC with OvC was performed by Eltabback et al [2] who assessed more than 40 characteristics in 50 PPC patients and 503 OvC patients. They found 3 differences between PPC patients and OvC patients. PPC patients were significantly older, had later menarche, and were less likely to have used perineal talc.

We could not assess the difference in age between PPC patients and OvC patients because the groups were matched for that parameter. However, when the median age of the PPC patients was compared with that of the total group of OvC patients (n = 1226), it

was significantly higher (66 vs 61 years, $P = .003$). With regard to the onset of menarche, we did not find a difference between the 2 groups. There was also no difference between PPC patients and OvC patients regarding other gynecologic variables such as parity, history of infertility, use of oral contraceptives, and median age at menopause. Although still controversial, the use of perineal talc has been implicated as an etiologic factor in Ovc.[21] The significant excess of perineal talc users among OvC patients compared with PPC patients observed by Eltabbach et al [2] was based on a relatively high proportion of users in both groups (48% and 26%, respectively). In the current study, the reported proportion of perineal talc users was very low in both groups. Although the difference did not reach significance, the proportion of perineal talc users among OvC patients was also higher than among PPC patients (7.1% and 2.5%, respectively). It was previously reported that OvC patients have a lower frequency of a clinical mumps history, despite similar infection rates. This has been construed to indicate an immunologic incompetence that may enable the development ofovarian carcinoma possibly through a direct etiologic role of mumps virus.[22] We found no difference between PPC patients and OvC patients with regard to a clinical mumps history.

Comparisons of survival in PPC patients and OvC patients have been inconsistent in various studies, being similar, [6,7,10, 13] poorer, [12,14,16] or better [15] in the former compared with the latter, the mean ranging from 17 to 28 months for PPC patients.[1] The median survival of our PPC patients was 33 months and was statistically not different than the survival of OvC patients. It is noteworthy that the lack of difference in median survival between the PPC and OvC groups remained even when the analysis was restricted for stage III only. In the OvC group, there was a significantly better survival in patients who had optimal cytoreduction, ie, diameter of largest residual tumor 2 cm or less. No such correlation was observed in PPC patients. Fromm et al [7], reporting on 74 PPC patients, also found that cytoreduction to residual tumor of 2 cm or less is not a prognostic factor. In contrast, in other studies,[19,20] it was found that optimally reduced PPC patients had a significantly longer survival than those in whom optimal cytoreduction was not achieved. However, in these studies the criterion for optimal cytoreduction was residual tumor 1 cm or less.

Several additional aspects ofPPC and OvC have been previously compared. It was found that antigenically the neoplasms are similar.[9] It has also been reported that although overexpression of p53 protein, p53 gene mutations and abnormal DNA content was similar in both tumors, the overexpression rate of Her-2/neo in OvC was twice compared with PPC.[23] We, as well as others,18,24 have recently reported a similar frequency of BRCA1/2 mutations in PPC and OvC patients. This finding has been interpreted to indicate that these mutations may predispose to PPC as well as OvC and that PPC is part of the hereditary breast-ovarian cancer syndrome. One of the main and probably most important differences between PPC and OvC concerns the origin of these tumors. Although sporadic as well as familial ovarian carcinoma is considered to be of monofocal origin, there is evidence that at least some cases of PPC are of multifocal origin.[1]

To the best of our knowledge, the current study reports the largest series of PPC patients. An additional advantage of our study is that it is population based and therefore includes

an unselected representative group of PPC patients. The main weakness of our study is that some results are based on retrospective and occasionally incomplete data abstracted from hospital records from various institutions. Obviously, our results are limited to Israeli Jewish women.

Although we adhered to the accepted Gynecologic Oncology Group criteria, we are aware of the possible misclassification of PPC. As has been pointed out, [25] some tumors classified as PPC according to these criteria may actually be small ovarian epithelial malignancies that find the peritoneum and omentum more favorable sites for growth than the ovary.

Our data confirm the many similarities between PPC and OvC observed in other studies. This supports the contention that PPC is a subset of OvC. Yet, in view of some clinical differences between the 2 malignancies observed in the present and other studies and mainly due to the important biomolecular difference concerning the clonal origin of the tumors, it cannot completely be ruled out that PPC is a separate disease entity. However, practically, these differences do not enable a preoperative distinction between the neoplasms.

Insert table then the Appendix:
Table IV Median survival of PPC and OvC patients according to stage, grade, volume ofascites, and diameter ofresidual disease

	PPC			OvC			
	No.	Survival	95%CI	No.	Survival	95%CI	P*
Total	95	33.0	22.6-46.4	117	30.0	20.2-39.8	NS
Stage III	86	33.0	23.9-42.1	98	35.0	26.2-43.8	NS
Grade 2,3 [+]	59	29.0	15.6-42.5	90	30.0	18.0-42.0	NS
Volume of ascites ≤ 1	8	36.0 [t]		17	66.0	14.4-117.6	NS
Volume of ascites > 1	55	34.0	22.4-45.6	33	30.0	18.8-41.3	NS
Residual disease ≤ 2 cm	43	29.0	12.9-45.1	44	44.0	12.3-75.7	.02
Residual disease > 2 cm	33	33.0	18.9-47.1	44	24.0	11.0-37.0	.5

* Difference between PPC and OvC
[+] In both groups there were too few patients with known G1 tumors for meaningful analysis.
[±] 95% CI could not be computed because no event occurred after the median time.

Appendix

The members of the National Israel Ovarian Cancer Group are as follows:

Shmuel Anderman, MD Marco Alteras, MD Shaul Anteby, MD Jack Atad, MD Amiram Avni, MD Amiram Bar-Am, MD Dan Beck, MD Uzi Beller, MD Gilad Ben-Baruch, MD Yehuda Ben-David, MD Izhar BenShlomo, MD Haim Biran, MD Moshe Ben Ami, MD Angela Chetrit, BSc Shlomit Cohen, MD Shulamit Cohen, MD Ram Dgani, MD Yehudit FishIer, MD Ami Fishman, MD Eitan Friedman, MD Ofer Gerner, MD Ruth Gershoni, MD Reuvit Halperin, MD Galit Hirsh-Yechezkel, MD David Idelman, MD Rafael Katan, MD Yuri Kopilovic, MD, MD Efrat Lahad, MD Liat Lerner Geva, MD Hanoch Levavi, MD Tal Levi, MD Albert Levit, MD Beatriz Lifschitz-Mercer, MD Flora Lubin, MSc R.D. Zohar Leviatan, MD Jacob Marcovich, MD Joseph Menczer, MD Baruch Modan, MD (Chairman) Hedva Nitzan, RN, MPH Moshe Oetinger, MD Tamar Perez, MD Benjamin Piura, MD David Schneider, MD Mariana Shteiner, MD Zion Tal, MD Chaim Yaffe, MD Ilana Yanai, MD Shifra Zohar, RN, BA.

References

1. Ellabbakh GH, Piver MS. Extraovarian primary peritoneal carcinoma. Oncology (Huntingt) 1998;12:813-9.
2. Ellabbakh GH, Piver MS, Natarajan N, Medin CJ. Epidemiologic differences between women with extraovarian primary peritoneal carcinoma and women with epithelial ovarian cancer. Obslet GynecoI1998;1:254-9.
3. Chou CS, Menzin AW, Leonard DGB, Rubin SC, Wheeler E. Primary peritoneal carcinoma: A review of the literature. Obstet Gynecol Surv 1999;54:323-35.
4. White CD. Papillary intraperitoneal neoplasia resembling ovarian carcinoma after removal of benign ovaries. W V Med 1 1993;89: 282-3.
5. Piver MS, lishi MF, Tsukada Y, Nova G. Primary peritoneal carcinoma after prophylactic oophorectomy in women with a family history of ovarian cancer: a report of the Gilda Radner Familial Ovarian Cancer Registry. Cancer 1993;71:2751-5.
6. Dalrymple lC, Bannatyne P, Russel P, Solomon Hl, Tattersall MHN, Atkinson K, et al. Extraovarian peritoneal carcinoma: a clinicopathological study of 31 cases. Cancer 1989;64: 11 0-5.
7. Fromm GL, Gershenson DM, Silva EG. Papillary serous carcinoma of the peritoneum. Obstet Gynecol 1990;75:75-89.
8. Lele SB, Piver MS, Matharu, Tsukadu Y. Peritoneal papillary carcinoma. Gynecol Oncol 1988;31 :315-20.
9. Wick MR, Mills SE, Dehner LP, Bollinger DJ, Fechner RE. Serous papillary carcinomas arising from the peritoneum and ovaries: a clinicopathologic and immunohistochemical comparison. Int 1 Gynecol Pathol 1989;8: 179-88.

10. Ransom DT, Patel SR, Keeney GL, Malkasian GD. Papillary serous carcinoma of the peritoneum: a review of 33 cases treated with platin-based chemotherapy. Cancer 1990;66:1091-4.
11. Altaras NM, Aviram R, Cohen **I,** Cordoba M, Weiss E, Beyth Y. Primary peritoneal papillary serous adenocarcinoma: clinical and management aspects. Gynecol Oncol 1991;40:230-6.
12. Killackey MA, Davis AR. Papillary serous carcinoma of the peritoneal surface: matched-case comparison with papillary serous ovarian carcinoma. Gynecol Oncol 1993;51:171-4.
13. Ben-Baruch G, Sivan E, Moran 0, Rizel S, Menczer 1, Seidman DS. Primary peritoneal serous papillary carcinoma: a study of 25 cases and comparison with stage III-IV ovarian papillary serous carcinoma. Gynecol Oncol 1996;60:393-6.
14. Halperin R, Zehavi S, Langer R, Hadas E, Bukovski **I,** Schneider D. Primary peritoneal serous papillary carcinoma: a new epidemiologic trend? A matched-case comparison with ovarian serous papillary cancer. Int J Gynecol Cancer 2001;11:403-8.
15. Mulhollan n, Silva EG, Tornos C, Guerrieri C, Fromm GL, Gershenson D. Ovarian involvement by serous surface papillary carcinoma. Int 1 Gynecol Pathol 1994;13:120-6.
16. Rothaker D, Mobius G. Varieties of serous surface papillary carcinoma in Northern Germany: a thirty year autopsy study. Int 1 Gynecol Pathol 1995;14:310-8.
17. Modan B, Hartge P, Hirsh-Yechezkel G, Chetrit A, Lubin F, Beller D, et al. Parity, oral contraceptives, and the risk of ovarian cancer among carriers and non carriers of a BRCAI or BRCA2 mutation. N Engl 1 Med 2001;345:235-40.
18. Menczer J, Chetrit A, Barda G, Lubin F, Fishier Y, Altaras M, et al. Frequency of BRCA mutations in primary peritoneal carcinoma in Israeli lewish women. Gynecol Oncol 2003;88: 58-61.
19. Piver MS, Eltabbakh GH, Hempling RE, Recio FO, Blumenson LE. Two sequential studies for primary peritoneal carcinoma: induction with weekly cisplatin followed by either cisplatindoxorubicin-cyclophosphamid or paclitaxel-cisplatin. Gynecol Oncol 1997;67:141-6.
20. Eltabbakh GH, Werness BA, Piver S, B1umenson LE. Prognostic factors in extraovarian primary peritoneal carcinoma. Gynecol OncoI1998;71:230-9.
21. Piver MS, Backer TR, Piedmont M, Sandecki AM. Epidemiology and etiology of ovarian cancer. Sermin Oncol 1991;18:177-85.
22. Menczer 1, Modan M, Ranon L, Golan A. Possible role of mumps virus in the etiology of ovarian cancer. Cancer 1979;43:1375-8.
23. Kowalski LD, Kanbour AI, Price FV, Finkelstein SD, Christopherson WA, Seski JC, et al. A case-matched molecular comparison of extraovarian versus primary ovarian carcinoma. Cancer 1997;79:1587-94.
24. Bandera CA, Schorge 10, Muto MG, Berkowitz RS, Rubin SC, Mok SC. BRCAI gene mutations in women with papillary serous carcinoma of the peritoneum. Obstet Gynecol 1998;92:596-600.
25. Scully RE. The Eltabbakh/Piver article reviewed. Oncology (Huntingt) 1998;12:820-5.

provide a sustained stimulus for macrophage activation. [16] In view of these suppositions, it is interesting to note that the prognosis in Hodgkin disease was found to be better when sarcoid-like lesions were present. [17] Sarcoid-like lesions are a potential cause of confusion in patients with malignancy because they may be misinterpreted as metastatic disease. Our case demonstrates the need for careful evaluation of patients with apparently recurrent cancer, as therapy could be altered or initiated on this wrongful presumption.

References

I. Wolbach 513. A new type of cell inclusion, not parasitic, associated with disseminated granulomatous lesions.J Med Kes 1911; 24:243-57.

2. Nickerson DA. Boeck's sarcoid. Report of six cases in which autopsies were made. Arch Pathol 1937;24:19-29.

3. Gorton G, Linell F. Malignant tumors and sarcoid reactions in regional lymph nodes. Acta Radiol 1957;47:381-92.

4. Gregorie HB, Othersen HB, Moore MP Jr. The significance of sarcoid·like lesions In association with malignant neoplasms. Am J Surg 1962;104:577-86.

5. Bodem Cr, Hamory BH, Taylor HM, Kleopfer L. Granulomatous bone marrow disease. A review of the literature and c1inicopathology analysis of 58 cases. Medicine(Baltimore) 1983;62:372-83.

6. Novak E, Gray LA. Dysgerminoma of *the* ovary. Am J Obstet Gynecol 1938;35:925-37.

7. Sailer S. Ovarian dysgerminoma. Am J Cancer 1940;38:473-82.

8. Schattenberg HJ, Harris WH Jr. Malignant granulosa *cell* lumor with pseudotubercles. Am J Pathol 1946;22:539-49.

9. Volckaert A, Van der Niepen P, De Hou MF, Van Hercke H, Van Beile S. Association of sarcoid-like lesions in the bone marrow with an adenocarcinoma of *the* ovary: Report of a case. Acta Clin Belg 1986;41:426-30.

10. Fanburg BL. Sarcoidosis. In: Wyngaarden JB. Smith LH, eds. *Cecil* textbook of medicine. 14th ed. Philadelphia: WB Saunders, 1988:451-7.

11. Brincker H. Coexistence of sarcoidosis and malignant disease: Causality or coincidence? Sarcoidosis 1989; 6:31-43.

12. Brincker H. Sarcoid reactions in malignant tumors. Cancer Treat Rev 1986;13:147-56.

13. Brincker H., Wilbek E. The incidence of malignant tumours in patients with respiratory sarcoidosis. Br J Cancer 1974;29:247-51.

14. Brincker H. Solid tumors preceding or following sarcoidosis. Med Pediatr Oncol 1987;15:82-8.

15. Trump DL. Ellinger OS. Feldman MJ, Dragon LH. 'Sarcoidosis' and sarcoid·like lesions: Their occurrence after cytotoxic and radiation therapy of testis cancer. Arch Intern Med 1981; 141:37-8.

16. Boros DL. Experimental granulomatous disease. In: Fanberg BL. ed. Sarcoidosis and other granulomatous disease of the lung. New York: Marcel Dekker, 1983:403-49.

17. Sacks EL, Donaldson SS, Gordon J, Dorfman RF. Epithelioid granulomas associated with Hodgkin's disease. Cancer 1978;41:562-7.

Address reprint requests to;
Thomas W. *Montag.* MD
Women's Cancer Center
1515 Trousdale, Suite 217
Burlingame, CA 94010

Received August 8, 1990.
Received in revised form December 10, 1990.
Accepted December 28, 1990.

Copyright 0 1991 by The American College or Obstetricians and Gynecologists.

PAPILLARY SEROUS CARCINOMA OF THE PERITONEUM FOLLOWING ENDOMETRIAL CANCER

Peter G. *Rose, MD, and Frank R. Reale, MD*

Two cases of advanced papillary serous carcinoma of the peritoneum occurred after hysterectomy and bilateral salpingo-oophorectomy for endometrial carcinoma. Careful resectioning of the original ovarian specimens failed to demonstrate a previously undiagnosed ovarian malignancy. In both cases, CA 125 levels, which were being followed routinely because of the previous endometrial cancer, rose before the diagnosis of peritoneal carcinoma and corresponded closely to patient response to therapy.' *(Obstet Gyneco178:980, 1991)*

Multiple primary adenocarcinomas of the upper genital tract, including the endocervix, endometrium, tube, and ovary, tend to occur in the same populations. [1-4] These patients are also at an increased risk for breast and colon carcinoma.[5 6] Because hysterectomy and bilateral salpingo-oophorectomy are commonly performed as primary therapy for genital neoplasia, a subsequent second upper genital tract malignancy is uncommon. A tumor marker for nonmucinous ovarian cancer, CA 125 lias been used to monitor patients treated for endometrial cancer.[7 8] Two patients, each with a previous diagnosis of endometrial carcinoma, had rapid elevations of CA 125. Both proved to have primary adenocarcinoma of the peritoneum.

Figure 1 Photomicrograph of the uterine wall (case 1) demonstrating nests of tubular glands with loss of stroma and definite "back-to-back" crowding. establishing the diagnosis of endometrial-type adenocarcinoma (hematoxylin and eosin, x 200).

Case Reports

Case 1

A 70-year·old white woman underwent exploratory laparotomy, peritoneal cytologic sampling, total hysterectomy, and bilateral salpingo-oophorectomy for endometrial adenocarcinoma diagnosed on D&C. Microscopic examination demonstrated a small focus of International Federation of Gynecology and Obstetrics (FIGO) grade 2 endometrial adenocarcinoma without myometrial invasion (Figure 1). Because peritoneal washings were positive for malignant *cells,* the patient received adjuvant megestrol acetate for 6 months. She had routine follow up examinations including history, physical examination, *chest* radiography, and serum CA 125 measurement. Although she had no symptoms and there was no clinical evidence of disease, at 24 months her CA 125, which had been less than 7.S IU/ml, increased to 30.5 IU/ml. Six months later she complained of vague abdominal

symptoms; her CA 125 was 400 IU/mL. Her symptoms rapidly progressed over the next week and CA 125 rose to 1694 IU/mL.

Abdominal and pelvic computed tomography (0) scan demonstrated ascites, an omental mass, and diffuse mesenleric thickening. Extensive upper abdominal disease was encountered at exploration. Cytoreduction was accomplished by omentectomy, resection of a tumor in the gastrocolic ligament, and splenectomy. Microscopic examination demonstrated a FIGO grade 3 serous papillary carcinoma, which differed from the histology of the previous endometrial cancer (Figure 2). The ovarian histology slides were reviewed carefully and the blocks resectioned, but no tumor was demonstrated. The patient's CA 125 levels have paralleled her response to therapy, subsequent recurrence, and response to subsequent therapy.

Figure 2. Subsequent peritoneal biopsy from case 1 showing a papillary serous adenocarcinoma with the usual pleomorphism, irregular cytoplasmic margins, large central nucleoli, and classic layered psammoma bodies (hematoxylin and eosin. x 600).

Figure 3. Microscopic section from the uterine wall (case 2), demonstrating the complex cribriform pattern of infiltrating endometrial-type adenocarcinoma. Normal endometrial glands are also present around the superficially invasive tumor (hematoxylin and cosin, x 100).

Case 2

A 54-year-old white woman, who had undergone mastectomy for breast cancer at age 37, was referred for evaluation for adjuvant radiation following an exploratory laparotomy, peritoneal cytologic sampling, total hysterectomy, and bilateral salpingo-oophorectomy for endometrial

carcinoma. The operative report was particularly detailed and included a complete upper abdominal exploration, which was normal. Tumor histology demonstrated FIGO grade 2 endometrial adenocarcinoma with invasion into the superficial third of the myometrium (Figure 3). Peritoneal washings were positive for malignant cells and serum CA 125 was 53.9 IU/mL. A repeat CA 125 evaluation 1 month later was 123 IU/mL, which rose to 171 IU/mL the following week. Although asymptomatic, the woman was advised to undergo an abdominal and pelvic CT scan, which demonstrated ascites and an omental mass. A paracentesis revealed malignant cells, and surgical exploration was performed.

At surgery, there was bulky upper abdominal disease involving the omentum and gastrocolic ligament. Cytoreduction to 0.5 cm was accomplished with the Cavitron Ultrasonic Surgical Aspirator (Valley Lab, Boulder, CO). The tumor was a FIGO grade 3 serous papillary carcinoma (Figure 4). The woman's CA 125 level normalized after one course of chemotherapy and remained less than 30 IU/mL throughout five more courses of chemotherapy. Evaluation for persistent disease by clinical examination, CT scan, and second-look laparotomy was negative, and the woman remains disease-free 12 months after diagnosis.

Figure 4. Histology from the abdominal tumor subsequently removed from case 2 shows a serous papillary adenocarcinoma identical to other intraperitoneal biopsies performed at the same procedure (hematoxylin and eosin. x 200).

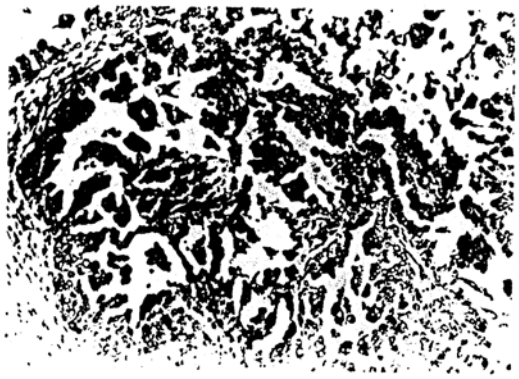

Discussion

Studies have demonstrated that peritoneal carcinoma and serous ovarian carcinoma are similar in biologic behavior and clinical response. [9,10] Tobacman et al reported three cases of peritoneal carcinoma after prophylactic oophorectomy in 28 patients with a history of familial epithelial ovarian cancer. The fact that these cancers tend to occur in the same women who may be prone to ovarian cancer suggests a common etiology. Whether the risk of developing peritoneal carcinoma can be altered by prophylactic oophorectomy is unknown.

Elevation of CA 125 is seen commonly after abdominal surgery for benign conditions and can persist for several months. 12 The minimally elevated CA 125 of the second patient was believed to be due to her recent surgery; however, when it continued to rise, further evaluation was initiated.

Elevated CA 125 levels are also predictive of recurrence in ovarian cancer patients. [13] Recently, CA 125 elevations have been reported to predict recurrence in endometrial

cancer patients, [7,8] although previous radiation therapy may falsely elevate CA 125 levels. The role of CA 125 monitoring in the early detection of tumors such as breast or colon cancer has not been studied. However, these tumors usually demonstrate elevated serum values only with advanced disease. [14] Monitoring of CA 125 levels after diagnosis of upper genital tract malignancy has become a commonly accepted practice. A continued rise in CA 125 levels usually signals recurrent disease. However, our two cases represent a different cause of CA 125 elevations. Peritoneal carcinoma should be considered when there is no evidence of recurrent primary disease.

References

1. Woodruff DJ, Solomon D, Sullivant H. Multifocal disease in the upper genital canal. Obstet GynecoI1987;65:695--8.
2. Russell P, Bannatyne PM, Solomon JH, Stodaard LD, Tattersall MHN. Multifocal tumorigenesis in the upper female genital tract - implications for staging and management. Int J Gynecol Pathol 1985;4:192-208.
3. Kaminski PF. Norris HJ. Coexistence of ovarian neoplasms and endocervical adenocarcinoma. Obstet Gynecol 1984;64:553--6.
4. Rose PG, Herterick EE. Boutselis JG. Moeshberger M. Sachs L. Multiple primary gynecologic neoplasms. Am J Obstet Gynecol 1987;157:261-7.
5. Curtis RE, Hoover RN. Kleinerman RA. Harvey EB. Second cancer following cancer of the female genital system in Connecticut, 1935--82. Natl Cancer Inst Monogr 1985;68:113--37.
6. Storm HH. Ewertz M. Second cancer following cancer of the female genital system in Denmark. 1943-80. Natl Cancer Inst Monogr 1985;68:331-40.
7. DukJM, AaldersJG, de Bruijn HWA. CA-125: A useful marker in e'ndometrial carcinoma. Am J Obslet Gynecol 1990;37:388--9.
8. Paslner B, Orr J, Mann WJ. Use of serum CA·125 measurement in posttreatment surveillance of early stage endometrial carcinoma. Am J Obstet Gynecol 1990;162:427-9.
9. Lele SB, Piver MS. Malharu J, Tsukada Y. Peritoneal papillary carcinoma. Gynecol Oncol 1988;31:315-20.
10. Fromm G. Gershenson DM, Silva EG. Papillary serous carcinoma of the peritoneum. Obstet Gynecol 1990;75:89-95.
11. Tobacman JK, Tucker MA, Kose R, et al. Intra-abdominal carcinomatosis after prophylactic oophorectomy in ovarian-cancer prone families. Lancet 1982;ii:795-7.
12. Talbot RW, Jacobsen DJ, Nagorney, DM, Malkasian GD. Ritts RE. Temporary elevation of CA 125 after abdominal surgical treatment for benign disease and cancer. Surg Gynecol Obstet 1989; 168:407-12.
13. Niloff JM, Knapp RC, Lavin PT, et al. The CA-I25 assay as a predictor of clinical recurrence in epithelial ovarian cancer. Am J Obstet Gynecol 1986;155:56-60.
14. Jacobs I. Bast C. The CA·125 tumour-associated antigen: A review of the literature. Hum Reprod 1989;4:1-12.

Reprints are not available.
Received September 5, 1990.
Received in revised form November 14, 1990.
Accepted November 26, 1990.

Copyright C 1991 by The American College of Obstetricians and Gynecologists.

Medicare Coverage Database

NCO for Tumor Antigen by Immunoassay – CA125 (40-17)
Is this a Lab **NCD**?
No

Publication Number
6

Manual Section Number
40-17

Effective Date of this Version
10/1/2003

Implementation Date
10/1/2003

Benefit Category
Diagnostic Laboratory Tests

Note: This may not be an exhaustive list of all applicable Medicare benefit categories for this item or service.

Coverage Topic
Diagnostic Tests, X-rays, and Lab Services
Lab Services

Item/Service Description
Description: Immunoassay determinations of the serum levels of certain proteins or carbohydrates serve as tumor markers. When elevated, serum concentration of these markers may reflect tumor size and grade.

This policy specifically addresses tumor antigen CA125.

Indications and Limitations of Coverage
Indications:

CA 125 is a high molecular weight serum tumor marker elevated in 80% of patients who present with epithelial ovarian carcinoma. It is also elevated in carcinomas of the fallopian tube, endometrium, and endocervix. An elevated level may also be associated with the presence of a malignant mesothelioma.

A CA125 level may be obtained as part of the initial pre-operative work-up for women presenting with a suspicious pelvic mass to be used as a baseline for purposes of post-operative monitoring. Initial declines in CA 125 after initial surgery and/or chemotherapy for ovarian carcinoma are also measured by obtaining three serum levels during the first month post treatment to determine the patient's CA 125 half-life, which has significant prognostic implications.

CA 125 levels are again obtained at the completion of chemotherapy as an index of residual disease. Surveillance CA125 measurements are generally obtained every 3 months for 2 years, every 6 months for the next 3 years, and yearly thereafter. CA 125 levels are also an important indicator of a patient's response to therapy in the presence of advanced or

recurrent disease. In this setting, CA 125 levels may be obtained prior to each treatment cycle.

Limitations:
These services are not covered for the evaluation of patients with signs or symptoms suggestive of malignancy. The service may be ordered at times necessary to assess either the presence of recurrent disease or the patient's response to treatment with subsequent treatment cycles.

CA 125 is specifically not covered for aiding in the differential diagnosis of patients with a pelvic mass as the sensitivity and specificity of the test is not sufficient. In general, a single "tumor marker" will suffice in following a patient with one of these malignancies.

CPT/HCPCS Codes

86304	IMMUNOASSAY FOR TUMOR ANTIGEN, QUANTITATIVE; CA 125

ICD-9 Codes Covered

180.0	MALIGNANT NEOPLASM OF ENDOCERVIX
182.0	MALIGNANTNEOPLASM OF CORPUS UTERI EXCEPT ISTHMUS
183.0	MALIGNANT NEOPLASM OF OVARY
183.2	MALIGNANT NEOPLASM OF FALLOPIAN TUBE
183.8	MALIGNANT NEOPLASM OF OTHER SPECIFIED SITES OF UTERINE ADNEXA
184.8	MAUGNANT NEOPLASM OF OTHER SPECIFIED SITES OF FEMALE GENITAL ORGANS

198.6	SECONDARY MALIGNANT NEOPLASM OF OVARY
198.82	SECONDARY MALIGNANT NEOPLASM OF GENITAL ORGANS
236.0 - 236.3	NEOPLASM OF UNCERTAIN BEHAVIOR OF UTERUS
V10.43 - V10.44	PERSONAL HISTORY OF MALIGNANT NEOPLASM OF OVARY

Reasons for Denial

Note: This section has not been negotiated by the Negotiated RuleMaking Committee. It includes CMS's interpretation of it's longstanding policies and is included for informational purposes. Tests for screening purposes that are performed in the absense of signs, symptoms, complaints, or personal history of disease or injury are not covered except as explicity authorized by statue. These include exams required by insurance companies, business establishments, government agencies, or other third parties. Tests that are not reasonable and necessary for the diagnosis or treatment of an illness or injury are not covered according to the statue. Failure to provide documentation of the medical necessity of tests may result in denial of claims. The documentation may include notes documenting relevant signs, symptoms, or abnormal findings that substantiate the medical necessity for ordering the tests. In addition, failure to provide independent verification that the test was ordered by the treating physician (or qualified nonphysician practitioner) through documentation in the physician's office may result in denial. A claim for a test for which there is a national coverage or local medical review policy will be denied as·not reasonable and necessary if it is submitted without an ICD-9-CM code or narrative diagnosis listed as covered in the policy unless other medical documentation justifying the necessity is submitted with the claim. If a national or local policy identifies a frequency expectation, a claim for a test that exceeds that expectation may be denied as not reasonable and necessary, unless it is submitted with documentation justifying increased frequency. Tests that are not ordered by a treating physician or other qualified treating nonphysician practitioner acting within the scope of their license and in compliance with Medicare requirements will be denied as not reasonable and necessary. Failure of the laboratory performing the test to have the appropriate Clinical Laboratory Improvement Act of 1988 (CLIA) certificate for the testing performed will result in denial of claims.

ICD-9 Codes Denied

798.0 - 798.9	SUDDEN INFANT DEATH SYNDROME
V15.85	PERSONAL HISTORY OF EXPOSURE TO POTENTIALLY HAZARDOUS BODY FLUIDS
V16.1	FAMILY HISTORY OF MALIGNANT NEOPLASM OF TRACHEA BRONCHUS AND LUNG
V16.2	FAMILY HISTORY OF MALIGNANT NEOPLASM OF OTHER RESPIRATORY AND INTRATHORACIC ORGANS
V16.40	FAMILY HISTORY OF MALIGNANT NEOPLASM OF GENITAL ORGAN UNSPECIFIED
V16.51 - V16.59	FAMILY HISTORY OF MALIGNANT NEOPLASM OF KIDNEY
V16.6	FAMILY HISTORY OF LEUKEMIA

V16.7	FAMILY HISTORY OF OTHER LYMPHATIC AND HEMATOPOIETIC NEOPLASMS
V16.8	FAMILY HISTORY OF OTHER SPECIFIED MALIGNANT NEOPLASM
V16.9	FAMILY HISTORY OF UNSPECIFIED MALIGNANT NEOPLASM
V17.0 - V17.8	FAMILY HISTORY OF PSYCHIATRIC CONDITION
V18.0 - V18.8	FAMILY HISTORY OF DIABETES MELLITUS
V19.0 - V19.8	FAMILY HISTORY OF BLINDNESS OR VISUAL LOSS
V20.0 - V20.2	HEALTH SUPERVISION OF FOUNDLING
V28.0 - V28.9	ANTENATAL SCREENING FOR CHROMOSOMAL ANOMALIES BY AMNIOCENTESIS
V50.0 – V50.9	ELECTIVE HAIR TRANSPLANT FOR PURPOSES OTHER THAN REMEDYING HEALTH STATES
V53.2	FITTING AND ADJUSTMENT OF HEARING AID
V60.0 - V60.9	LACK OF HOUSING
V62.0	UNEMPLOYMENT
V62.1	ADVERSE EFFECTS OF WORK ENVIRONMENT
V65.0	HEALTHY PERSON ACCOMPANYING SICK PERSON
V65.11	PEDIATRIC PREBIRTH VISIT FOR EXPECTANT MOTHER
V65.19	OTHER PERSON CONSULTING ON BEHALF OF ANOTHER PERSON
V68.0 - V68.9	ISSUE OF MEDICAL CERTIFICATES
V70.0 - V70.9	ROUTINE GENERAL MEDICAL EXAMINATION AT A HEALTH CARE FACILITY
V73.0 - V73.99	SCREENING EXAMINATION FOR POLIOMYELITIS
V74.0 - V74.9	SCREENING EXAMINATION FOR CHOLERA
V75.0 - V75.9	SCREENING EXAMINATION FOR RICKETTSIAL DISEASES
V76.0	SPECIAL SCREENING FOR MALIGNANT NEOPLASMS OF THE RESPIRATORY ORGANS
V76.3	SCREENING FOR MALIGNANT NEOPLASMS OF THE BLADDER
V76.42 - V76.9	SCREENING FOR MALIGNANT NEOPLASMS OF THE ORAL CAVITY
V77.0 - V77.99	SCREENING FOR THYROID DISORDERS
V78.0 - V78.9	SCREENING FOR IRON DEFICIENCY ANEMIA
V79.0 - V79.9	SCREENING FOR DEPRESSION
V80.0 - V80.3	SCREENING FOR NEUROLOGICAL CONDITIONS
V81.0 - V81.6	SCREENING FOR ISCHEMIC HEART DISEASE
V82.0 - V82.9	SCREENING FOR SKIN CONDITIONS

ICD-9 Codes That Do Not Support Medical Necessity
Any ICD-9 code not listed in either of the ICD-9-CM sections.

Sources of Info/Basis for Decision for Labs:
Clinical Pancreatic Guideline for the Use of Tumor Markers in Breast and Colorectal Cancer, American Society of Clinical Oncology. J Clin Oncol 14:2843-2877, 1996.

Chan OW, Beveridge RA, Muss H, et al. Use of Triquant BR Radioimmunoassay for Early Detection of Breast Cancer Recurrence in Patients with Stage II and Stage III Disease. J Clin Oncol 1977, 15(6):2322-2328.

Coding Guidelines for Labs:
1. Any claim for a test listed in "HCPCS CODES" above must be submitted with an ICD-9-CM diagnosis code or comparable narrative. Codes that describe symptoms and signs, as opposed to diagnoses, should be provided for reporting purposes when a diagnosis has not been established by the physician. (Based on Coding Clinic for ICD-9-CM, Fourth Quarter 1995, page 43.)

2. Screening is the testing for disease or disease precursors so that early detection and treatment can be provided for those who test positive for the disease. Screening tests are performed when no specific sign, symptom, or diagnosis is present and the patient has not been exposed to a disease. The testing of a person to rule out or to confirm a suspected diagnosis because the patient has a sign and/or symptom is a diagnostic test, not a screening. In these cases, the sign or symptom should be used to explain the reason for the test. When the reason for performing a test is because the patient has had contact With, or exposure to, a communicable disease, the appropriate code from category VOl, Contact with or exposure to communicable diseases, should be assigned, not a screening code, but the test may still be considered screening and not covered by Medicare. For screening tests, the appropriate ICD-9-CM screening code from categories V28 or V73-V82 (or comparable narrative) should be used. (From Coding Clinic for ICD-9-CM, Fourth Quarter 1996, pages 50 and 52)

3. A three-digit code is to be used only if it is not further subdivided. Where fourth-digit and/or fifth-digit subclassifications are provided, they must be assigned. A code is invalid if it has not been coded to the full number of digits required for that code. (From Coding Clinic for ICD-9-CM. Fourth Quarter, 1995, page 44.)

4. Diagnoses documented as "probable," "suspected," "questionable," "ruleout," or "working diagnosis" should not be coded as though they exist. Rather, code the condition(s) to the highest degree of certainty for that encounter/visit, such as signs, symptoms, abnormal test results, exposure to communicable disease or other reasons for the visit. (From Coding Clinic for ICD-9-CM, Fourth Quarter 1995, page 45.)

5. When a non-specific ICD-9-CM code is submitted, the underlying sign, symptom or condition must be related to the indications for the test above.

Documentation Requirements for Labs:
Indicated if service request for CA125 is requested more frequently than stipulated.

Transmittal Number
AB-03-104

Transmittal Link
http://www.cms.hhs.gov/Transmittals/Downloads/AB03104.pdf

Revision History

3/5/2002 Administrative Policies Related to Processing Claims for Clinical Diagnostic Laboratory Services, AB-02-030 (CR 1998), effective February 23, 2002.

6/26/2002 Delay in Enforcement of National Coverage Determinations (NCDs) for Clinical Diagnostic Laboratory Services, AB-02-087 (CR 2203). This PM delayed enforcement of the NCDs from 11/25/2002 to 01/01/2003.

7/31/2002 Implementation of National Coverage Determinations Regarding Clinical Diagnostic Laboratory Services, AB-02-110 (CR 2130). This PM provides the 23 clinical diagnostic laboratory service NCDs. ThiS PM is 231 pages in length.

9/27/2002 Claims Processing Requirements for Clinical Diagnostic Laboratory Services Based on the Negotiated Rulemaking, AB-02-129 (CR 2169). 10/4/2002 Questions and Answers Related to Implementation of National Coverage Determinations for Clinical Diagnostic Laboratory Services, AB-02134 (CR 2382.)

10/2/2003 Changes to the Laboratory National Coverage Determination (NCD) Edit Software for October 1, 2003, AB-03-104 (CR 2814). Effective and implementation dates 10/01/03.