

## Coverage Request for DecisionDx DiffDx-Melanoma (Z00BS)

### Description of request

Difficult-to-diagnose melanocytic neoplasms with uncertain malignant potential are an important clinical problem, for (a) dermatopathologists who face the challenge of providing a clear and accurate diagnosis and (b) dermatologists who need a clear diagnosis to support treatment and patient management decisions. Approximately 300,000 melanocytic lesions each year cannot be confidently diagnosed as benign or malignant by H&E staining alone.<sup>1-3</sup> Today, dermatopathologists resolve their diagnoses by consultation with colleagues, immunohistochemical studies (IHC), and adjunctive molecular testing such as gene expression, however, significant uncertainty often remains after employment of these tools due to substantial levels of diagnostic discordance among dermatopathologists and limitations in the accuracy and application of currently available molecular testing.<sup>2-7</sup> The impact of this ambiguity can result in misdiagnosis or missed diagnosis of melanoma, both of which have considerable impact on patient care. Unnecessary re-excisions, sentinel lymph node biopsies, and increased follow-up may result from misdiagnosis of a diagnostically challenging benign lesion, whereas a diagnostically challenging melanoma inappropriately classified as a benign nevus may result in under-treatment for a potentially deadly disease.<sup>8-10</sup> Castle Biosciences has developed the DecisionDx DiffDx-Melanoma test, a 35-gene expression profile test (35-GEP), with intended use in primary cutaneous melanocytic neoplasms or for which malignant potential is uncertain.<sup>11,12</sup> This is an adjunctive diagnostic test to characterize lesions as benign or malignant when used in the context of other clinical, laboratory and histopathologic information. Note that in April 2019, Palmetto MolDX posted a final LCD for a similar gene expression profile test (Myriad MyPath Melanoma, a 23-gene expression profile test [23-GEP] [ZB041, L37859]) that has also been validated as an adjunctive diagnostic aid for invasive melanocytic neoplasms of uncertain malignant potential.

**Importantly, DecisionDx DiffDx-Melanoma has improved accuracy, technical success, and definitive result delivery compared to other molecular assays available on the market and specifically the 23-GEP test and meets reasonableness and medical necessity criteria (Appendix A). Therefore, and as a result of our October 21, 2020 informal meeting, we are requesting a reconsideration of LCD L37859 to include DecisionDx DiffDx-Melanoma that would convert LCD L37859 to a foundational LCD and include DecisionDx DiffDx-Melanoma in the accompanying coverage and billing article.**

Based upon our discussions, the reconsideration request for conversion of the existing LCD to a foundational LCD as well as the coverage and billing article should be straightforward; however, we recommend a change to the coverage limitations. Specifically, the initial LCD limited coverage to tests ordered by board-certified dermatopathologists. Based upon interviews with dermatologists and dermatopathologists, it is clear that dermatopathologists may often issue a skin biopsy pathology report that contains diagnostic uncertainty, due to inability to arrive at a definitive diagnosis or by arriving at a definitive diagnosis that conveys ambiguity [i.e., melanocytic tumor of unknown malignant potential (MELTUMP)]. As such, decisions for patient management, including primary lesion surgical management decisions, falls to board-certified dermatologists or other treating clinicians. Published studies for both the 35-GEP and the 23-GEP show clinical utility of GEP tests for dermatologists to assist in the decision to avoid surgical procedures when a benign diagnosis is supported by GEP test results. These interview findings were discussed with the Palmetto MolDX Medical Directors on October 21, 2020 and, separately, with the Noridian Medical Directors on November 13, 2020. Both groups of Medical Directors were in alignment to list both board-certified dermatopathologists and board-certified dermatologists within the coverage limitations. In addition, during the call with the Noridian Medical Directors, it was noted that treating clinicians with expertise in management of skin cancer are not limited to board certified dermatologists, and, especially in areas where dermatology specialty access is limited, other treating

clinicians such as primary care providers also make the same surgical management decisions. As such, the attached, proposed foundational LCD contains language to enable ordering in this scenario.

## Background

Suspicious pigmented lesions result in over 5 million biopsies per year in the United States. From those biopsies, approximately 200,000 invasive cutaneous melanomas (CM) and melanoma in situ (MIS) will be diagnosed. The early and accurate diagnosis of CM is critical for favorable patient outcomes, where CM with low tumor depth (thin Breslow depth) have survival rates >98%.<sup>13,14</sup> The current gold standard for diagnosis is the visual examination of hematoxylin and eosin (H&E) stained biopsy tissue by a dermatopathologist using light microscopy. Though sufficient for many lesions, a significant portion of lesions have high diagnostic discordance and/or ambiguous features that require second opinions or adjunctive tests.<sup>2-5,7,15</sup> A definitive diagnosis of either benign nevus or malignant melanoma leads to divergent management strategies, and correct, early diagnosis is a key determinant in patient outcomes.<sup>16,17</sup>

## Current Diagnostic Pathway

A dermatologist (or less commonly a primary care physician) is the initial provider to identify or evaluate a pigmented lesion suspicious for melanoma.

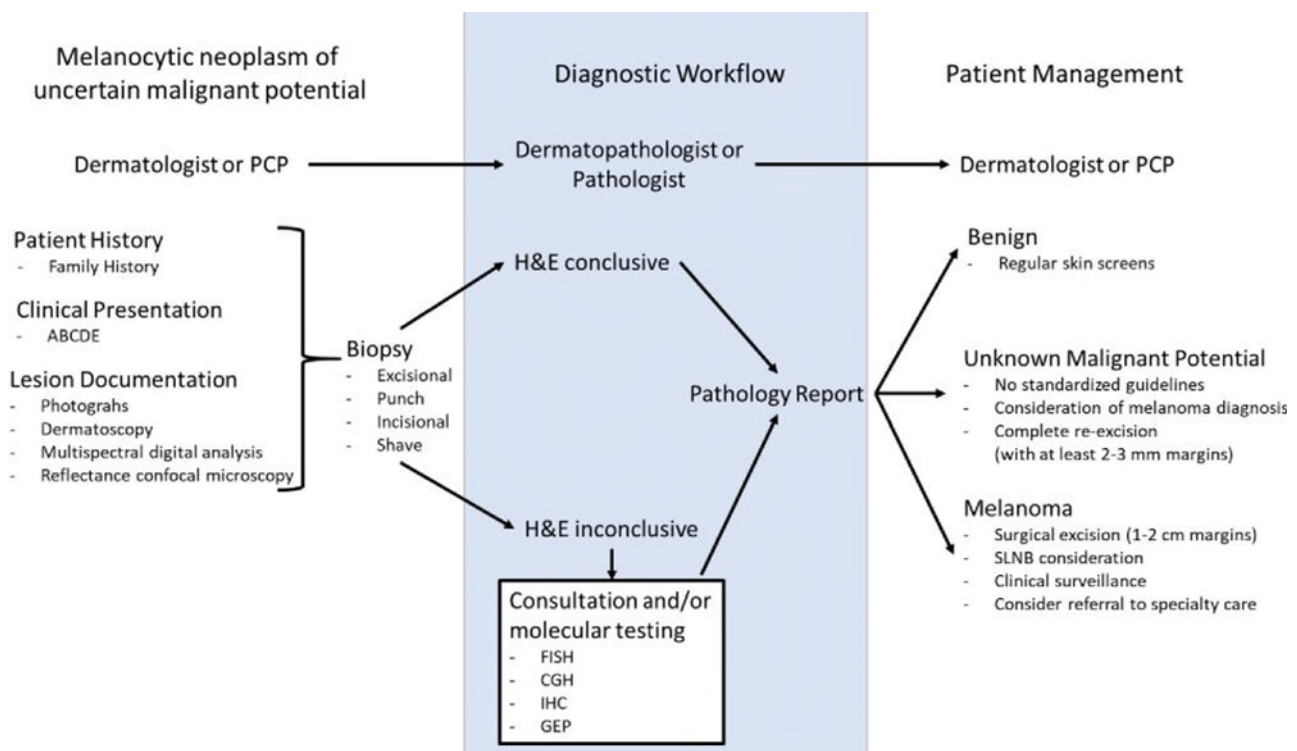
In the case of suspicious pigmented lesions, the ABCDE classification system is typically used to evaluate the likelihood of the lesion to be melanoma. Lesion asymmetry, border, color, diameter, and evolving status are used to identify lesions with higher possibility of being malignant. Other characteristics, including change in sensation (i.e. pain, itchy) or change in the surface of the lesion (i.e. dry, bleeding) are evaluated and noted. Documentation of lesion characteristics may include photographs and/or dermoscopy. Based on the combination of patient history and risk of malignancy determined by clinical examination, a biopsy may be recommended to assess the lesion at the cellular and molecular level to render a diagnosis. Biopsy type can depend on lesion location and size. Although shave biopsies (saucerization technique) are frequently used for the diagnosis of suspicious pigmented lesions, this technique carries the risk of transecting the base of a lesion which can result in difficulty in accurately measuring tumor depth.<sup>18</sup> Punch and incisional biopsies can also be used for the diagnosis of melanoma, however, the preferred method is an excisional biopsy where the entire lesion is removed if there is significant clinical concern for melanoma. Tissue is processed and stained with hematoxylin and eosin (H&E) and reviewed by a dermatopathologist using a microscope. The subsequent identification of the histologic features of melanoma such as asymmetry, atypical melanocytes, dermal mitosis, and pagetoid infiltration of melanocytes may result in a diagnosis of melanoma.

In approximately 15% of biopsies, a definitive diagnosis cannot be made by H&E visualization alone, and additional consultation and/or adjunctive molecular tests such as IHC, fluorescence in situ hybridization (FISH), comparative genomic hybridization (CGH), and gene expression profiling (GEP) may be performed. Each of these tests has strengths and weaknesses resulting in additional information that may be useful in establishing a diagnosis.<sup>1-3,19-24</sup>

- FISH queries four to six chromosomal loci through hybridization of fluorescent probes and evaluation by visualization of the tissue. Limitations in application of FISH include (i) possible false negative results in melanomas without alterations at the interrogated loci, (ii) possible false positives when polyploidy is present, (iii) insufficient signal for interpretations results in 5-30% of cases, and (iv) subjectivity of

analysis due to significant inter-observer variability from varied probe sets, cut-off thresholds and skill/experience of observers and laboratories.<sup>25–29</sup>

- SNP array/aCGH methodologies interrogate the genome more broadly and quantification of signal does not involve subjective human interpretation. However, the requirement for ~40% homogeneity in tumor specimens means that aberrations in cell subpopulations may go undetected. In addition, SNP array/aCGH requires a relatively large quantity of tissue, restricting use to thicker tumors, and the significance of some detected aberrations is unknown.<sup>30–32</sup>
- MyPath Melanoma is a 23-gene expression profile that evaluates expression of RNA transcripts produced by 14 discriminant genes and 9 stably-expressed control genes for normalization.<sup>33–35</sup> Detection of a genetic signature of malignancy by a gene expression profile is objective and reproducible. However, the test has technical limitations including a technical failure rate of 14.7% and an indeterminate result in 10-12% of results. Thus, as many as one-quarter of cases submitted for testing will not yield definitive results.<sup>33–35</sup>



**Figure 1. Diagnostic pathway for patients with melanocytic neoplasms suspicious for melanoma.**

A final pathology report, including adjunctive testing results, is sent to the dermatologist and a clinical management plan is discussed with the patient based on the established diagnosis. For benign lesions, no additional follow-up is typically recommended, and the patient continues routine skin screening as usual. If a diagnosis of melanoma is received, clinical staging (i.e., depth of tumor, presence of ulceration, clinical examination of nodal basin) are performed to assess initial prognosis and treatment recommendations.<sup>36</sup> Gene expression profiling may also be obtained at this time for additional prognostic information to inform treatment plan decisions in the context of clinical stage. Surgical resection by wide local excision with a margin of 1-2 cm is the primary treatment for the majority of melanoma patients. Additional management decisions regarding lymph node biopsy, imaging and adjuvant therapy are also based on prognostic information.

If a definitive diagnosis of benign nevus or malignant melanoma is unable to be determined, as is the case with approximately 15-25% of lesions that undergo adjunctive testing, and malignant potential of the lesion remains uncertain and is commonly treated as the worst-case differential diagnosis, resulting in unnecessary re-excisions and increased clinical follow-up. **Thus, arriving at a definitive diagnosis of malignant versus benign lesion has profound implications for patient management.**<sup>8-10</sup>

## DecisionDx DiffDx-Melanoma Overview

### Intended Use

The DecisionDx DiffDx-Melanoma 35-gene expression profile (GEP) is intended for use in patients with primary cutaneous melanocytic neoplasms with equivocal histopathology or for which malignant potential is uncertain. This adjunctive test aids in characterizing these lesions as benign or malignant and should be interpreted in the context of other clinical, laboratory, and histopathologic information to assist dermatopathologists in arriving at a correct diagnosis of melanoma versus non-melanoma and to aid dermatologists and other treating clinicians with the interpretation of skin biopsy reports to inform patient management decisions.<sup>11,12</sup>

### Test Description

DecisionDx DiffDx-Melanoma is a multigene expression test that analyzes 32 discriminant genes demonstrated to have differential expression between benign nevi and malignant melanoma lesions and 3 control genes (Appendix B). This 35-gene expression profile (35-GEP) test is performed on formalin-fixed paraffin-embedded (FFPE) tumor tissue biopsy specimens of a patient's primary melanocytic neoplasm. The test uses a neural network algorithm to classify lesions as benign (GEP suggestive of benign neoplasm), malignant (GEP suggestive of melanoma), or intermediate-risk (GEP cannot exclude malignancy).<sup>11</sup> The test has proven analytic validity, clinical validity, and clinical utility.<sup>11,12</sup>

### Clinical Validity

To identify a diagnostic signature capable of classification of malignancy, deep machine learning was applied to training cohort gene expression data (n=416 [200 benign nevi and 216 malignant melanoma specimens]) in a prospectively designed archival biomarker study. Benign specimens were reviewed by at least three dermatopathologists and inclusion in both the training and independent validation cohort required diagnostic concordance by at least 2 dermatopathologists. The modeling was performed using neural networks to develop the final test selected for validation, which was comprised of one gene expression signature, where the presence of spitzoid and/or MIS features was incorporated with two algorithms. The gene expression signature generates probability scores which are used to classify the lesions as benign, intermediate-risk, or malignant.

The DecisionDx DiffDx-Melanoma test was validated in an independent cohort of 503 diagnostically concordant melanocytic neoplasms including 273 benign nevi representing 8 subtypes and 230 melanomas representing 9 subtypes.<sup>11</sup> Within the validation cohort, DecisionDx DiffDx-Melanoma generated definitive benign or malignant results in the majority of lesions tested and demonstrated highly accurate classification (**Table 1**). Importantly, only 3.6% of specimens from patients of all ages and 3.8% of specimens in patients  $\geq 18$  years old received the intermediate-risk results. Technical success of the test was achieved in 96.6% of lesions tested. In the Medicare population, the test maintained high accuracy in classification of malignancy and low rate of intermediate-risk test results.

**Table 1. Accuracy of DecisionDx DiffDx-Melanoma in validation cohort in patients of all ages, over the age of 18 years, and in Medicare population**

	All ages (n=503)		Age > 18 years (n=478)		Age ≥ 65 years (n=178)	
	35-GEP	95% CI	35-GEP	95% CI	35-GEP	95% CI
Sensitivity	99.1%	97.9-100%	99.1%	97.9-100%	99.2%	97.6-100%
Specificity	94.3%	91.5-97.1%	96.2%	93.8-98.6%	100%	100-100%
PPV	93.6%	90.5-96.7%	96.1%	93.6-98.6%	100%	100-100%
NPV	99.2%	98.1-100%	99.1%	97.9-100%	98.1%	94.3-100%
Intermediate -risk result	3.6%		3.8%		3.4%	

Samples that fall in intermediate-risk zone were excluded from the calculation.

PPV- positive predictive value; NPV – negative predictive value; CI – confidence interval.

The 35-GEP accurately classified melanoma lesions as malignant in 14/14 desmoplastic melanomas, 25/26 lentigo maligna, 15/15 nevoid, 59/60 nodular, 72/77 superficial spreading, and 17/19 MIS lesions. Nevi were also appropriately classified as benign for 42/45 blue, 96/99 common nevi, 82/91 dysplastic nevi, and 26/36 Spitz nevi. Six out of seven Spitz nevi classified as malignant occurred in pediatric patients; thus, additional studies are being undertaken to confirm the performance of the test in pediatric patients. When compared to other currently available ancillary tests, DecisionDx DiffDx-Melanoma has similar or improved sensitivity and specificity, reduced technical failures and more diverse inclusion of both benign and malignant subtypes in development and validation. (Table 2)

**Table 2. Comparison of 35-GEP to other ancillary molecular diagnostic tools (adapted from Estrada 2020).<sup>11</sup>**

Study	Number of cases	Type of test	Sensitivity	Specificity	Technical failure	Nevi subtypes included	Melanoma subtypes included
Current study	503	35-GEP	99.1%	94.3%	3.4%	Blue, common, deep penetrating, dysplastic, Spitz	Acral, desmoplastic, lentiginous, lentigo maligna, in situ, nevoid, nodular, superficial spreading, spitzoid
Clarke et al. <sup>41</sup>	437	23-GEP	94.0%	90.0%	14.7%	Blue, common, dysplastic, Spitz	Acral, lentigo maligna, nodular, superficial spreading
Clarke et al. <sup>40</sup>	736	23-GEP	91.5%	92.5%	NA	Not reported	Acral, lentigo maligna, nodular, superficial spreading
Gerami et al. <sup>92</sup>	196	FISH <sup>#</sup>	86.7%	95.4%	NA	Acral, blue, common, dysplastic, Spitz	Not reported
Gerami et al. <sup>93</sup>	233	FISH <sup>#</sup>	83.0%	94.0%	NA	Blue, common, dysplastic, Spitz	Acral, lentigo maligna, nodular, superficial spreading
Lezcano et al. <sup>24</sup>	400	PRAME IHC	84.7% <sup>&amp;</sup>	99.2% <sup>&amp;</sup>	NA	Common, dysplastic, Spitz	Acral, cutaneous paramucosal, desmoplastic, lentigo maligna, nevoid, nodular, superficial spreading
Lezcano et al. <sup>87</sup>	110	PRAME IHC	75.0%	98.8%	NA	Blue, common, deep penetrating, dysplastic, Spitz	Acral, malignant melanoma, nevoid, spitzoid

<sup>#</sup> 6p25, Cep 6, 6q23, and 11q13

<sup>&</sup> Calculated from the data reported in the manuscript.

NA – not addressed.

## Clinical Utility

The clinical need and utility of adjunctive diagnostic tools for diagnosis of melanocytic neoplasms has been previously demonstrated.<sup>37,38</sup> Specifically, for the Myriad MyPath 23-GEP test, intended for use as an adjunctive diagnostic aid for melanocytic lesions with equivocal histopathology or for which malignant potential is uncertain, the impact on improving dermatopathologist's diagnoses of melanoma versus non-melanoma as well as the impact on dermatologists' patient management has been demonstrated. Comparison of pre- and posttest diagnoses of diagnostically challenging melanocytic neoplasms demonstrated a 56% increase in definitive diagnoses and an 42.7% overall change in diagnosis. Change in treatment recommendations for 49% of patients and 76.6% of changes aligned to test result. In a cohort of patients with pretest diagnoses of "indeterminate", patient management changes by dermatologists were assessed after the GEP testing provided a definitive diagnosis. The treatment differed from pretest recommendations in 71.4% of cases and excisions were reduced by 63.2% in benign lesions. Taken together, these studies suggest that Medicare beneficiaries with diagnostically challenging primary cutaneous melanocytic neoplasms, for whom GEP is used to establish a diagnosis, may have improved outcomes by comparison to untested patients, as defined by an increase in accurate diagnoses and reduction in burdensome and unnecessary treatments.

A clinical utility study of DecisionDx DiffDx-Melanoma 35-GEP demonstrated similar findings to that of Myriad MyPath 23-GEP. Sixty difficult-to-diagnose lesions that were diagnostically discordant or designated as unknown malignant potential by 3 to 5 expert dermatopathologists were tested with DecisionDx DiffDx-Melanoma.<sup>12</sup> Six dermatopathology study participants reviewed the cases with and without test results to determine if the results demonstrated diagnostic utility and impacted treatment recommendations. In addition, fourteen board-certified dermatologists reviewed case details and a pathology report with and without test results to determine impact on patient management. After receiving the DecisionDx DiffDx-Melanoma result, individual diagnosis changes were observed in 41.7% of cases and diagnostic confidence was increased in 51% of cases. Dermatologists treatment recommendations were also impacted by DecisionDx DiffDx-Melanoma test results.<sup>12</sup> In lesions with benign test results, willingness to observe the lesion and not provide additional treatment was increased in 69% of responses. Lesion excisions for cases with benign result were decreased in 76.7% of responses and appropriately remained the same for malignant lesions. This would have resulted in a net reduction in the number of surgeries performed for difficult-to-diagnose melanocytic neoplasms, due to the focused reduction of interventions in those cases that received a benign GEP result. **Thus, DecisionDx DiffDx-Melanoma test informs similar changes in individual diagnoses by dermatopathologists and similar reduction in re-excisions of benign lesions in patient management recommendations by dermatologists as have been reported for the Myriad MyPath Melanoma test, confirming the clinical utility of both GEP tests for this intended use**<sup>12,37,38</sup> (Table 3).

**Table 3. Comparison of demonstrated clinical utility of DecisionDx DiffDx-Melanoma and Myriad MyPath gene expression assay.**

	<b>Myriad MyPath Melanoma 23-Gene Expression Assay</b>	<b>Castle Biosciences 35-Gene Expression Assay</b>
Overall change in diagnoses in difficult-to-diagnose lesions by dermatopathologists	42.7%	41.7%
Changes in diagnosis concordant with test results	76.6%	88.1%
Reduction in re-excision of biopsy with benign test result by dermatologists	63.2%	76.7%

**Outcome improvement: Informed management decisions on management of melanocytic neoplasms compared to GEP with current coverage indications.**

An indirect chain of evidence linking improved diagnostic accuracy and clarity with patient management decisions can demonstrate improvement in outcomes in patients tested with DecisionDx DiffDx-Melanoma. In addition, because a test with similar clinical utility is currently available with coverage indication, outcome improvement can also be constructed by comparison of DecisionDx DiffDx-Melanoma to the Myriad MyPath Melanoma assay by demonstration that DecisionDx DiffDx-Melanoma has improved technical success, accuracy of results, and provides more definitive results with the same clinical utility as Myriad MyPath Melanoma.

<p><b>Does the 35-GEP test as an adjunctive diagnostic aid for melanocytic neoplasms accurately classify lesions as benign or malignant?</b></p>	<p>Yes. The 35-GEP demonstrated highly accurate classification of lesions as benign or malignant in an independent validation of 503 primary cutaneous melanocytic neoplasms. Technical success was achieved in 96.6% of specimens, 96.4% of results demonstrated a definitive test result. The test had sensitivity of 99.1% and specificity of 94.3% in patients of all ages. Specificity was improved to 96.2% in patients ≥18 years of age.<sup>11</sup></p>
<p><b>Is diagnostic classification of the 35-GEP at least as good as alternative methods?</b></p>	<p>Yes. Molecular testing for melanocytic neoplasms with uncertain or equivocal histopathology is included as viable adjunctive diagnostic tools in NCCN guidelines, including the existing gene expression profile test.<sup>36</sup> These tests are to be used as diagnostic adjuncts and interpreted in the context of clinical and histopathological findings to clarify the diagnosis.</p> <p>Compared to the currently available 23-GEP, the 35-GEP has substantial improvements that enhance diagnostic classification, including (i) equivalent or improved sensitivity and specificity, (ii) reduced indeterminate/intermediate-risk results that fail to resolve diagnostic uncertainty, (iii) improved technical success, and (iv) inclusion of additional lesion subtypes in development and validation.<sup>33-35</sup></p> <p>Compared to other available diagnostic aids such as CGH, FISH, and PRAME IHC, the 35-GEP has advantages of improved accuracy, providing an objective result that is not subjected to human interpretation, and production of results from a single laboratory to eliminate site-to-site variability and enhance reproducibility of results.<sup>26-32</sup></p>

<p><b>Are different diagnostic groups associated with different management interventions?</b></p>	<p>Yes. According to the NCCN guidelines, patients with a diagnosis of malignant melanoma or melanoma in situ should be treated with surgical excision of the lesion with clinical margins of 0.5 cm-1.0 cm for melanoma in situ and 1.0-2.0 cm for invasive melanoma dependent on thickness of the tumor.<sup>36</sup> Sentinel lymph node biopsy may also be performed to predict the patient's individual risk. In contrast, patients with benign neoplasms typically receive no further treatment and continue with regular follow-up and clinical surveillance for additional lesions.</p> <p>Unnecessary re-excisions, sentinel lymph node biopsies, and increased follow-up may result from a diagnostically challenging benign lesion, whereas a diagnostically challenging melanoma inappropriately diagnosed as benign may result in under-treatment and progression to late-stage melanoma.<sup>8-10</sup></p> <p>Thus, diagnostic accuracy has enormous implications for patient care.</p>
<p><b>Has treatment according to diagnostic groups been demonstrated to improve outcomes?</b></p>	<p>Yes. Surgical intervention can be curative for many patients with early-stage melanoma, however, delay in diagnosis and treatment can result in regional and systemic disease spread (i.e., Stage III – Stage IV disease) significantly worsening patient prognosis.<sup>13,14</sup> Conversely, diagnostic uncertainty in patients with melanocytic neoplasms of uncertain malignant potential can result in overdiagnosis of melanoma and overtreatment of benign lesions and unnecessary re-excisions.</p> <p>In recognition of the impact of accurate diagnosis on patient outcomes, the Association for Molecular Pathology (AMP) has recognized that “accurate diagnosis has inherent clinical utility and is foundational to directing patient care to improve clinical outcomes”.<sup>39</sup></p>

The indirect chain of evidence shows that improving diagnostic clarity focuses surgical interventions on the appropriate patients, reducing the risk of both a missed diagnosis and misdiagnosis of melanoma. Early surgical intervention in patients with melanoma results in improved prognosis, whereas delay in treatment may result in regional or systemic disease spread (i.e., Stage III – Stage IV disease) and poorer prognosis. Reducing re-excisions in patients with difficult-to-diagnose benign lesions improves utilization of healthcare resources and improved net health outcomes.

### Outcome improvement: Summary

The evidence summarized above shows that the DecisionDx DiffDx-Melanoma test **is an analytically and clinically validated test that is a highly accurate adjunctive diagnostic test for patients with primary cutaneous melanocytic neoplasms of uncertain malignant potential** and has a positive impact on net health outcomes. The test improves over the current, clinically available 23-GEP test by having reduced technical failure, reduced indeterminate/intermediate risk results, and improved sensitivity (**Table 4**).



**Table 4. Comparison of DecisionDx DiffDx-Melanoma to Myriad MyPath gene expression assay.**

	<b>Myriad MyPath Melanoma 23-Gene Expression Assay</b>	<b>Castle Biosciences 35-Gene Expression Assay</b>
Number of Genes	23	35
Intended Use	The test is intended for evaluation of primary cutaneous melanocytic neoplasms for which the diagnosis of malignant melanoma versus benign nevus is equivocal / uncertain	
Technical Failure	14.7%	<b>3.4%</b>
Sensitivity	91.5 - 94.0%	<b>99.1%</b>
Specificity	90.0 - 92.5%	<b>94.3%</b>
PPV	79.4 - 89.7%*	<b>93.6%</b>
NPV	94.9 - 97.2%*	<b>99.2%</b>
Result	Benign, indeterminate, malignant	Benign, intermediate-risk, malignant
% indeterminate/ intermediate zone	10 - 12%	<b>3.6%</b>
TAT	5-7 days (lab to report)	5-7 days (lab to report)

\*Not reported; calculated from data in publication

Consistent with NCCN guidelines, the result of this test can guide diagnosis of these difficult-to-diagnose lesions when interpreted in the context of clinical and histopathological features.<sup>36</sup> Accurate diagnosis of melanoma is of acute importance as early surgical intervention is associated with high cure rates and improved prognosis. The **benefit of enhanced diagnostic clarity informed by the DecisionDx DiffDx-Melanoma test result is that patients with diagnostically challenging benign lesions can be spared unnecessary surgical intervention, while re-excisions and enhanced clinical surveillance can be focused on those with diagnostically challenging melanomas, resulting in more efficient utilization of healthcare resources.**

#### Cited Literature

1. Shoo BA, Sagebiel RW, Kashani-Sabet M. Discordance in the histopathologic diagnosis of melanoma at a melanoma referral center. *J Am Acad Dermatol.* 2010;62(5):751-756. doi:10.1016/j.jaad.2009.09.043
2. Farmer ER, Gonin R, Hanna MP. Discordance in the histopathologic diagnosis of melanoma and melanocytic nevi between expert pathologists. *Hum Pathol.* 1996;27(6):528-531. doi:10.1016/s0046-8177(96)90157-4
3. Patrawala S, Maley A, Greskovich C, et al. Discordance of histopathologic parameters in cutaneous melanoma: Clinical implications. *J Am Acad Dermatol.* 2016;74(1):75-80. doi:10.1016/j.jaad.2015.09.008
4. Damsky WE, Bosenberg M. Melanocytic nevi and melanoma: unraveling a complex relationship. *Oncogene.* 2017;36(42):5771-5792. doi:10.1038/onc.2017.189
5. Elmore JG, Barnhill RL, Elder DE, et al. Pathologists' diagnosis of invasive melanoma and melanocytic proliferations: observer accuracy and reproducibility study. *BMJ.* 2017;357:j2813. doi:10.1136/bmj.j2813
6. Elmore JG, Elder DE, Barnhill RL, et al. Concordance and Reproducibility of Melanoma Staging According to the 7th vs 8th Edition of the AJCC Cancer Staging Manual. *JAMA Netw Open.* 2018;1(1):e180083-e180083. doi:10.1001/jamanetworkopen.2018.0083

7. Fryback DG, Thornbury JR. The Efficacy of Diagnostic Imaging. *Med Decis Making*. 1991;11(2):88-94. doi:10.1177/0272989X9101100203
8. Glazer A, Cockerell C. Histopathologic discordance in melanoma can have substantial impacts on patient care. *SKIN J Cutan Med*. 2019;3(2):85. doi:10.25251/skin.3.2.41
9. McGinnis KS, Lessin SR, Elder DE, et al. Pathology review of cases presenting to a multidisciplinary pigmented lesion clinic. *Arch Dermatol*. 2002;138(5):617-621. doi:10.1001/archderm.138.5.617
10. Hawryluk EB, Sober AJ, Piris A, et al. Histologically challenging melanocytic tumors referred to a tertiary care pigmented lesion clinic. *J Am Acad Dermatol*. 2012;67(4):727-735. doi:10.1016/j.jaad.2012.02.036
11. Estrada SI, Shackelton JB, Cleaver NJ, et al. Development and validation of a diagnostic 35-gene expression profile test for ambiguous or difficult-to-diagnose suspicious pigmented skin lesions. *SKIN J Cutan Med*. 2020;Accepted.
12. Farberg A, Ahmed K, Bailey C, et al. A 35-Gene Expression Profile Test for use in Suspicious Pigmented Lesions Impacts Clinical Management Decisions of Dermatopathologists and Dermatologists. *SKIN J Cutan Med*. 2020;4(6):523-533. doi:10.25251/skin.4.6.4
13. Melanoma Survival Rates. Melanoma Research Alliance. Accessed June 22, 2020. <https://www.curemelanoma.org/about-melanoma/melanoma-staging/melanoma-survival-rates/>
14. Lo SN, Scolyer RA, Thompson JF. Long-Term Survival of Patients with Thin (T1) Cutaneous Melanomas: A Breslow Thickness Cut Point of 0.8 mm Separates Higher-Risk and Lower-Risk Tumors. *Ann Surg Oncol*. 2018;25(4):894-902. doi:10.1245/s10434-017-6325-1
15. Piepkorn MW, Longton GM, Reisch LM, et al. Assessment of Second-Opinion Strategies for Diagnoses of Cutaneous Melanocytic Lesions. *JAMA Netw Open*. 2019;2(10):e1912597. doi:10.1001/jamanetworkopen.2019.12597
16. High WA. Malpractice in Dermatopathology—Principles, Risk Mitigation, and Opportunities for Improved Care for the Histologic Diagnosis of Melanoma and Pigmented Lesions. *Clin Lab Med*. 2008;28(2):261-284. doi:10.1016/j.cll.2007.12.006
17. Troxel DB. Pitfalls in the Diagnosis of Malignant Melanoma: Findings of a Risk Management Panel Study. *Am J Surg Pathol*. 2003;27(9):1278–1283.
18. Elston DM, Stratman EJ, Miller SJ. Skin biopsy: Biopsy issues in specific diseases. *J Am Acad Dermatol*. 2016;74(1):1-16; quiz 17-18. doi:10.1016/j.jaad.2015.06.033
19. Diwan AH, Lazar AJ. Nevoid Melanoma. *Clin Lab Med*. 2011;31(2):243-253. doi:10.1016/j.cll.2011.03.002
20. DeWane ME, Kelsey A, Oliviero M, Rabinovitz H, Grant-Kels JM. Melanoma on chronically sun-damaged skin: Lentigo maligna and desmoplastic melanoma. *J Am Acad Dermatol*. 2019;81(3):823-833. doi:10.1016/j.jaad.2019.03.066
21. King R. Lentiginous Melanoma. *Arch Pathol Lab Med*. 2011;135(3):337-341. doi:10.1043/2009-0538-RA.1

22. Harms KL, Lowe L, Fullen DR, Harms PW. Atypical Spitz Tumors: A Diagnostic Challenge. *Arch Pathol Lab Med*. 2015;139(10):1263-1270. doi:10.5858/arpa.2015-0207-RA
23. Yang GB. Risk and Survival of Cutaneous Melanoma Diagnosed Subsequent to a Previous Cancer. *Arch Dermatol*. 2011;147(12):1395. doi:10.1001/archdermatol.2011.1133
24. Magro CM, Crowson AN, Mihm MC. Unusual variants of malignant melanoma. *Mod Pathol*. 2006;19(2):S41-S70. doi:10.1038/modpathol.3800516
25. Díaz A, Valera A, Carrera C, et al. Pigmented spindle cell nevus: clues for differentiating it from spindle cell malignant melanoma. A comprehensive survey including clinicopathologic, immunohistochemical, and FISH studies. *Am J Surg Pathol*. 2011;35(11):1733-1742. doi:10.1097/PAS.0b013e318229cf66
26. Abásolo A, Vargas MT, Ríos-Martín JJ, Trigo I, Arjona A, González-Cámpora R. Application of fluorescence in situ hybridization as a diagnostic tool in melanocytic lesions, using paraffin wax-embedded tissues and imprint-cytology specimens. *Clin Exp Dermatol*. 2012;37(8):838-843. doi:10.1111/j.1365-2230.2012.04416.x
27. Clemente C, Bettio D, Venci A, et al. A fluorescence in situ hybridization (FISH) procedure to assist in differentiating benign from malignant melanocytic lesions. *Pathologica*. 2009;101(5):169-174.
28. Gerami P, Jewell SS, Blondin B, et al. Fluorescence In Situ Hybridization (FISH) as an Ancillary Diagnostic Tool in the Diagnosis of Melanoma. *Am J Surg Pathol*. 2009;33(8):11.
29. Gerami P, Li G, Pouryazdanparast P, et al. A highly specific and discriminatory FISH assay for distinguishing between benign and malignant melanocytic neoplasms. *Am J Surg Pathol*. 2012;36(6):808-817. doi:10.1097/PAS.0b013e31824b1efd
30. Bastian BC, LeBoit PE, Hamm H, Bröcker EB, Pinkel D. Chromosomal gains and losses in primary cutaneous melanomas detected by comparative genomic hybridization. *Cancer Res*. 1998;58(10):2170-2175.
31. Bastian BC, Olshen AB, LeBoit PE, Pinkel D. Classifying melanocytic tumors based on DNA copy number changes. *Am J Pathol*. 2003;163(5):1765-1770. doi:10.1016/S0002-9440(10)63536-5
32. Gaiser T, Kutzner H, Palmedo G, et al. Classifying ambiguous melanocytic lesions with FISH and correlation with clinical long-term follow up. *Mod Pathol Off J U S Can Acad Pathol Inc*. 2010;23(3):413-419. doi:10.1038/modpathol.2009.177
33. Clarke LE, Warf MB, Flake DD, et al. Clinical validation of a gene expression signature that differentiates benign nevi from malignant melanoma. *J Cutan Pathol*. 2015;42(4):244-252. doi:10.1111/cup.12475
34. Clarke LE, Flake DD, Busam K, et al. An independent validation of a gene expression signature to differentiate malignant melanoma from benign melanocytic nevi. *Cancer*. 2017;123(4):617-628. doi:10.1002/cncr.30385
35. Ko JS, Matharoo-Ball B, Billings SD, et al. Diagnostic Distinction of Malignant Melanoma and Benign Nevi by a Gene Expression Signature and Correlation to Clinical Outcomes. *Cancer Epidemiol Biomarkers Prev*. 2017;26(7):1107-1113. doi:10.1158/1055-9965.EPI-16-0958

36. Swetter SM, Thompson JA, Coit DG, et al. NCCN Clinical Practice Guidelines in Oncology. Cutaneous Melanoma. Version 3.2020. Published online May 18, 2020.
37. Cockerell CJ, Tschen J, Evans B, et al. The influence of a gene expression signature on the diagnosis and recommended treatment of melanocytic tumors by dermatopathologists: *Medicine (Baltimore)*. 2016;95(40):e4887. doi:10.1097/MD.0000000000004887
38. Cockerell C, Tschen J, Billings SD, et al. The influence of a gene-expression signature on the treatment of diagnostically challenging melanocytic lesions. *Pers Med*. 2017;14(2):123-130. doi:10.2217/pme-2016-0097
39. Joseph L, Cankovic M, Caughron S, et al. The Spectrum of Clinical Utilities in Molecular Pathology Testing Procedures for Inherited Conditions and Cancer: A Report of the Association for Molecular Pathology. *J Mol Diagn JMD*. 2016;18(5):605-619. doi:10.1016/j.jmoldx.2016.05.007

## Appendix A - DecisionDx-SCC Meets Medical Necessity and Reasonableness Standards

Criteria to be Medically Reasonable and Necessary	DecisionDx DiffDx-Melanoma Qualifications
Proven Clinical Utility	Clinical utility of DecisionDx DiffDx-Melanoma for improved diagnostic clarity by dermatopathologists and patient management decisions by dermatologists has been demonstrated in a published clinical utility study. This study demonstrates changes in individual diagnoses, increased diagnostic concordance and confidence among dermatopathologists following test results. Dermatologists also demonstrated changes in patient management plans following DecisionDx DiffDx-Melanoma test results, including increased likelihood to monitor benign lesions through clinical follow-up only and reduced re-excisions of benign lesions. These results verify the clinical utility of GEP testing in uncertain melanocytic neoplasms demonstrated for the 23-GEP, a test with the same intended use.
Positive impact on health outcomes	Accurate diagnosis of difficult-to-diagnose lesions has a profound impact on patient management decisions as benign lesions are typically followed through routine clinical surveillance, whereas melanoma is treated with additional surgical intervention, and depending on clinical staging factors, consideration for sentinel lymph node biopsy, imaging, increased follow-up, and referral for adjuvant therapy. Correct, early diagnosis of melanoma is critical for patient outcomes, as surgical intervention of early-stage, thin melanoma is commonly curative, and patients have favorable outcomes. In contrast, a missed diagnosis of melanoma can result in disease progression prior to treatment, to regional or systemic involvement (i.e., Stage III – Stage IV disease), and considerably worse prognosis. Uncertainty regarding the malignant potential of benign melanocytic lesions commonly results in treatment for the worst-case differential diagnosis, resulting in unnecessary re-excisions and increased clinical follow-up.
In line with generally accepted professional medical standards; accepted in the medical community as safe and effective for the condition in which it is used	National guidelines include ancillary molecular testing for melanocytic lesions in which malignant potential is uncertain, and treatment recommendations are based on the ultimate diagnosis, including all clinical, pathological, and molecular diagnostic information.
Consistent with the disease diagnosed	The test is intended to be used for patients with primary cutaneous melanocytic lesions with equivocal histopathology or for which malignant potential is uncertain.
Provided at the most appropriate level in a manner that is safe and effective for the patient	The test is a proprietary gene expression test that is only available through Castle Biosciences, Inc. The test is ordered on biopsy specimen during the existing diagnostic workflow at the time as other ancillary molecular diagnostic tests.
Proven clinical validity	One prospectively designed archival multi-center study has demonstrated clinical validity.
Proven analytic validity	Analytical performance studies have shown the test is accurate, reproducible, and reliable.

**Appendix B.** Discriminant genes included in the DecisionDx-DiffDx Melanoma test

<b>Gene classification</b>	<b>Gene symbol</b>	<b>Gene name</b>
Barrier function	HAL	Histidine ammonia-lyase
Barrier function	MGP	Matrix Gla protein
Barrier function	CST6	Cystatin-M
Barrier function	GJA1	Gap junction alpha-1 protein
Barrier function	CSTA	Cystatin A
Barrier function	CLCA2	Calcium-activated chloride channel regulator 2
Cytoskeleton involved	KRT17	Keratin, type I cytoskeletal 17
Cytoskeleton involved	PPL	Periplakin
Cytoskeleton involved	KRT2	Keratin 2
Cytoskeleton involved	ABLIM1	Actin binding LIM protein 1
Cytoskeleton involved	DSP	Desmoplakin
Cytoskeleton involved	NES	Nestin
Gene regulation	KLF5	Kruppel-like factor 5
Gene regulation	GATA3	GATA binding protein 3
Gene regulation	BAP1	Ubiquitin carboxyl-terminal hydrolase BAP1
Gene regulation	TP63	Tumor Protein P63
Gene regulation	SAP130	Histone deacetylase complex subunit SAP130
Gene regulation	SFN	14-3-3 protein sigma
Melanin Biosynthesis	GPR143	G-protein coupled receptor 143
Melanin Biosynthesis	WIPI1	WD repeat domain phosphoinositide-interacting protein 1
Melanin Biosynthesis	DCT	Dopachrome tautomerase
Melanin Biosynthesis	ATP6V0E2	ATPase H <sup>+</sup> transporting V0 subunit E2
Melanin Biosynthesis	PTN	Pleiotrophin
Protein synthesis	RPS16	40S ribosomal protein S16
Protein synthesis	RPL37A	60S ribosomal protein L37a
Tumorigenesis	BCL2A1	Bcl-2-related protein A1
Tumorigenesis	BTG1	Protein BTG1
Tumorigenesis	ANXA8L1	Annexin A8-like protein 1
Tumorigenesis	DUSP4	Dual specificity protein phosphatase 4
Tumorigenesis	CXCL14	C-X-C motif chemokine 14
Tumorigenesis	S100A8	Protein S100-A8
Tumorigenesis	S100A9	Protein S100-A9
<i>Housekeeping</i>	<i>FXR1</i>	<i>RNA binding protein</i>
<i>Housekeeping</i>	<i>HNRNPL</i>	<i>mRNA function protein</i>
<i>Housekeeping</i>	<i>YKT6</i>	<i>ER membrane protein</i>